

# Research Paper: Clinically-relevant Variations in the Origin and Course of the Radial Artery



Smitha Elizabeth<sup>1\*</sup> , Nitin Vishwakarma<sup>1</sup>

1. Department of Anatomy and Neurobiology; College of Medicine and Health Sciences, National University of Science and Technology, Sohar, Sultanate of Oman.



**Citation** Elizabeth S, Vishwakarma N. Clinically-relevant Variations in the Origin and Course of the Radial Artery. Anatomical Sciences. 2021; 18(1):7-14.



## Article info:

**Received:** 04 Aug 2020

**Accepted:** 10 Nov 2020

**Available Online:** 01 Jan 2021

## Keywords:

Radial artery, Axillary artery, Brachial artery, Course

## ABSTRACT

**Introduction:** The radial artery is an essential artery supplying the structures in the forearm. Variations in the radial artery concerning its origin, course, branching pattern, and mode of termination have been commonly reported. The high origin of the radial artery from either brachial or axillary artery was detected in numerous studies. Clinically-radial artery is used in cardiac catheterization and bypass graft; thus, the knowledge of these variations is of utmost significance to the surgeons.

**Methods:** In the present study, dissection was conducted on 51 upper limb specimens. The explored specimens were obtained from the College of Medicine and Health Sciences (NUST), Oman. Moreover, variations observed in the origin and course of the radial artery were noted and later photographed.

**Results:** Out of the 51 upper limb specimens studied, variation in the origin of the radial artery was observed from the axillary artery in one specimen and the brachial artery in 3 limbs. The course of these varied arteries was superficial in the forearm.

**Conclusion:** The knowledge of the variations in the origin and course of the radial artery will help prevent any untoward side effects that can occur during any procedures involving the radial artery.

## \* Corresponding Author:

Smitha Elizabeth, MD.

**Address:** Department of Anatomy and Neurobiology College of Medicine and Health Sciences, National University of Science and Technology Sohar, Sultanate of Oman.

**Tel:** +96 (89) 8026903

**E-mail:** smithakore3@gmail.com

## 1. Introduction

**V**ariations in the radial artery have been reported in studies on cadavers and angiographic images [1]. The variations observed were mostly in the origin and proximal course of the radial artery, rather than its distal course and termination [2]. The radial artery is the smaller part of the two terminal branches of the brachial artery arising in the cubital fossa. The proximal two-thirds of the radial artery courses underneath the brachioradialis muscle; whereas the distal third of the radial artery becomes superficial. Besides, it is positioned between the tendons of the brachioradialis and flexor carpi radialis [3].

The variant high origin of the radial artery is explained as the radial artery arising either from the brachial or axillary artery [4]. It may later pass superficial to the brachioradialis muscle in the forearm [5]. The knowledge of the variations in the radial artery is clinically important, as it is often used in interventional cardiology.

A study was conducted on retrograde radial arteriography among 650 patients undergoing their first transradial coronary procedure. Subsequently, the obtained findings suggested a high origin of the radial artery in 40(6.2%) of the study patients [6].

A retrospective study examined 602 images of routine angiographies of radial artery performed during cardiac catheterization. Accordingly, the most frequent anatomic variation was detected to be the high origin of the radial artery (5.1%) [7].

The prerequisite knowledge of radial arterial variations is essential for cardiologists as well as plastic and orthopedic surgeons. Furthermore, it is equally imperative for interventional radiologists and paramedical technicians to avoid serious complications [8].

## 2. Materials and Methods

The present study was performed on 51 embalmed cadaveric upper limb specimens. The examined specimens were obtained from the collection of formalin preserved 27 upper limb specimens and 12 upper limbs of cadavers; they are used for routine dissection by the undergraduate students in the Department of Anatomy and Neurobiology, College of Medicine and Health Science (COMHS), National University of Science and Technology (NUST), Sultanate of Oman, for 2 years.

These specimens and cadavers were obtained from the anatomy lab of the Medical School of West Virginia University (WVU), United States of America (USA); the cadavers and upper limb specimens were dissected, fixed, and preserved in the formalin based solution. These specimens were later provided to the COMHS, NUST.

None of the explored cadavers presented any pathological lesions, traumatic lesions, or surgical procedures in the upper limb. The required sample size was calculated by the following Equation [9]:

$$n = Z^2 \times (p \times q) / e^2 = (1.96)^2 \times 0.908 \times (1 - 0.908) / (0.08)^2 = 50.1$$

where, n=minimum required sample size; Z=1.96 for 95% Confidence Interval (CI); p=prevalence of the normal origination of radial artery as 90.8%; e=margin of error, 8%.

According to this calculation,  $\geq 51$  samples were required, i.e., the sample size available and used in the present study. The arteries in the upper limb were appropriately cleaned. Moreover, their course, relations, and branches were studied in detail and the variations were noted. The ethical standards of managing cadavers for teaching and learning purposes were followed during the procedures. The necessary photographs were taken under good lighting, using a Canon EOS 750D Digital SLR camera, and were labeled later.

## 3. Results

In the 51 upper limbs studied, variations were observed in 4 upper limb specimens. The variations were detected in the origin and course of the radial artery. In a left side upper limb specimen, the radial artery arose from the third part of the axillary artery. It passed in the axilla, between the medial and lateral root of the median nerve initially. It later crossed the lateral root of the median nerve passing laterally to the brachial artery in the arm. In the cubital fossa, it coursed laterally to the brachial artery. After entering the forearm, it passed downward superficial to pronator teres muscle. It ran along the medial side of the brachioradialis muscle. Furthermore, it had a superficial course through the forearm, lying just beneath the deep fascia. The further course of the radial artery was normal in the hand. The brachial artery continued as the ulnar artery in the forearm and had a normal course (Figures 1 & 2).

In another upper limb specimen of the left side, a branch arose from the brachial artery at the midarm level; con-

**Table 1.** Comparing the high origin of the radial artery with previous studies

| Author, Year [Ref.]      | Sample Size (N) | No. (%)                  |  |  |
|--------------------------|-----------------|--------------------------|--|--|
|                          |                 | Limbs Showing Variations | Origin of Radial Artery from Axillary Artery | Origin of Radial Artery from Brachial Artery |
| Haladaj et al. 2018 [11] | 120             | 11 (9.2)                 | 2 (1.67)                                     | 9 (7.5)                                      |
| Nasr AY, 2012 [4]        | 100             | 8                        | 1  | 7  |
| Yang et al. 2008 [18]    | 304             | 37 (12.17)               | 37 (12.17)                                   | -  |
| Kadel et al. 2019 [9]    | 53              | 7 (13.2)                 | 1 (1.8)                                      | 6 (11.3)                                     |
| Agarwal et al. 2016 [1]  | 32              | 1 (3.12)                 | 1 (3.12)                                     | -  |
| Zhan et al. 2010 [14]    | 1,200           | 3 (0.25)                 | -  | 3 (0.25)                                     |
| Present study, 2020      | 51              | 4 (7.84)                 | 1 (1.96)                                     | 3 (5.9)                                      |

ANATOMICAL SCIENCES

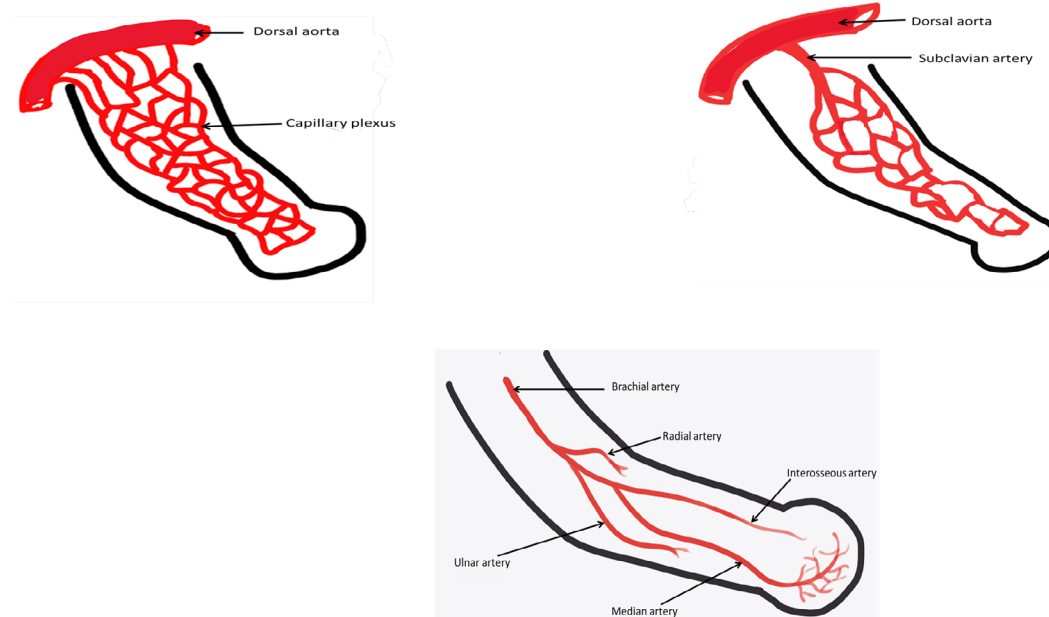
sequently, it coursed lateral to the brachial artery in the arm and later continued as the radial artery in the forearm. The radial artery presented a superficial course in the forearm, lying just beneath the deep fascia (Figure 3).

A similar variation was observed in two other specimens of the right side; a branch arose from the brachial artery in the proximal part of the arm and continued as a radial artery in the forearm. In all these 4 limbs, the course of the radial artery was superficial in the forearm.

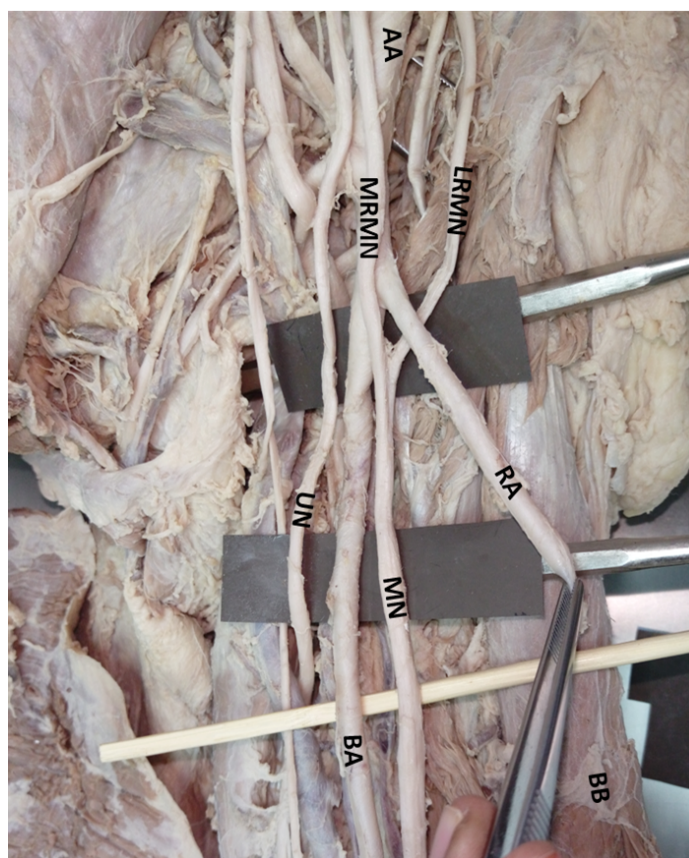
#### 4. Discussion

Variations in the major arteries of the upper limbs have been reported by several authors, and range between 11% and 24% [10]. A high origin of the radial artery from either brachial or axillary artery was the most common arterial variation detected. Besides, its incidence varies from 4.17% to 15.6% in cadavers and embryos, while 8% to 24.4% in angiographic studies [4].

In the study, a high origin of the radial artery was specified in 4 limb specimens. In 3(5.26%) specimens, they arose from the brachial artery at the midarm level; however, in 1(1.75%) specimen, they arose from the axillary artery.

**Figure 4.** Stages in the development of the arteries of the arm

ANATOMICAL SCIENCES



## ANATOMICAL SCIENCES

**Figure 1.** Radial artery after arising from the axillary artery crosses the lateral root of the median nerve and passes lateral to the brachial artery in the arm

AA: Axillary Artery; MRMN: Medial Root of Median Nerve; LRMN: Lateral Root of Median Nerve; BA: Brachial Artery; RA: Radial Artery; UN: Ulnar Nerve; MN: Median Nerve; BB: Biceps Brachii Muscle.

Haladaj et al. examined 120 randomly selected and isolated upper limbs. Subsequently, they found a high origin of the radial artery in 9.2% of the total number of limbs. Moreover, in two cases, they arose from the axillary artery; however, in 9 cases, they arose from the brachial artery. Anastomosis between the brachioradial and normal brachial arteries in the cubital fossa was also noted in their study [11].

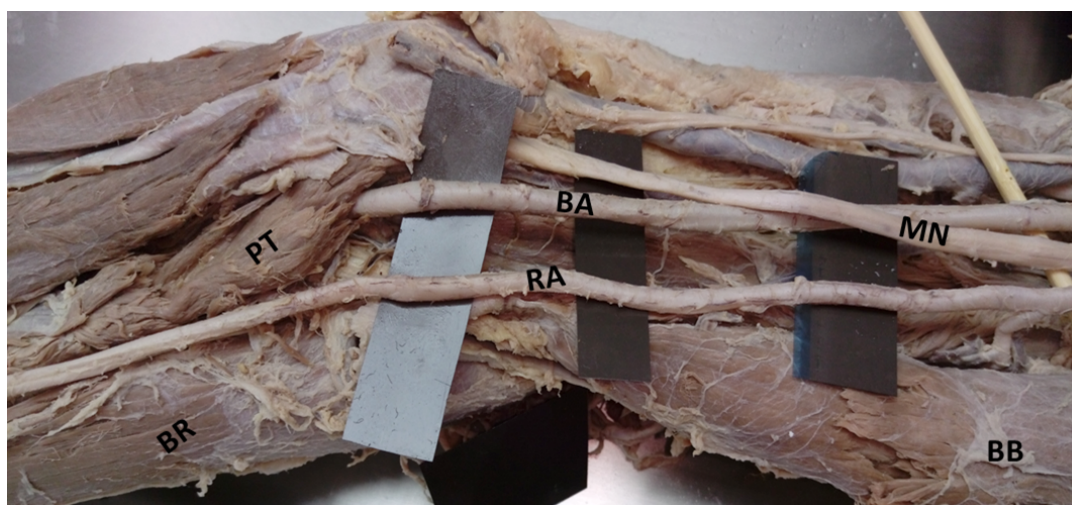
A case in which radial artery arose from the axillary artery in both the limbs in a cadaver was reported by Icten and associates [12]. Patnaik, V.V.G. et al. also described a case of high origin of radial artery from the third part of the axillary artery [13]. Rodriguez-Niedenfuhr et al. studied 384 upper limbs [5]. They defined the high origin of the radial artery from the brachial as the brachioradial artery; further, as a superficial brachioradial artery if the radial artery presented a superficial course in the forearm. In the 384 upper limbs studied by them, brachioradial artery was observed in 53(13.8%) specimens. In 23% of the cases, the brachioradial artery originated from the axillary artery; in 65.4% from the upper third of

the brachial artery; in 7.7% from the middle third of the brachial artery, and in 3.9% from the lower third of the brachial artery. However, only in one of the limbs, the high origin radial artery generated a superficial course in the forearm.

In another study on 100 upper limbs, a high origin of the radial artery was observed in 8 limbs; the radial artery arose from the brachial artery in 7 upper limbs and the axillary artery in a single limb [4]. In various other studies in different regions, the high origin of the radial artery was also detected as a prevalent variation [12-14].

In the present study, in addition to the high origin of the radial artery, the course of the radial artery was superficial in the forearm in all 4 limbs. The variant radial artery passed superficial to the pronator teres muscle and later medial to the brachioradialis muscle, i.e., unlike the normal course; the radial artery is overlapped by the brachioradialis muscle in its proximal third [3]. In the distal forearm, the radial artery was only covered by skin and antebrachial fascia.





ANATOMICAL SCIENCES

**Figure 2.** Radial artery passes superficial to the pronator teres to enter into the forearm and runs superficially in the forearm. The brachial artery enters the cubital fossa and later continues as an ulnar artery in the forearm.

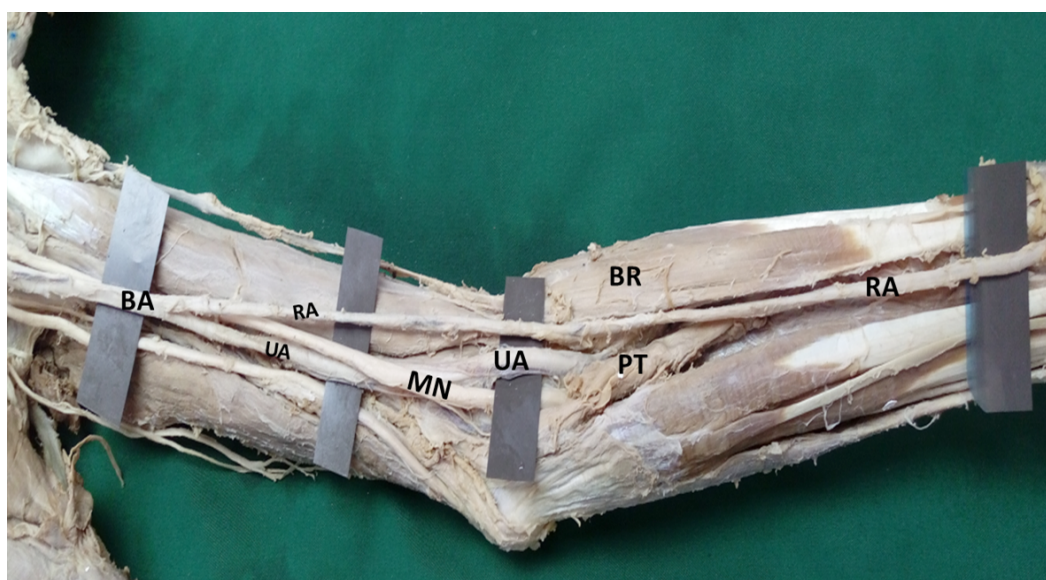BA: Brachial Artery; RA: Radial Artery; MN: Median Nerve; BB: Biceps Brachii Muscle; BR: Brachioradialis Muscle; PT: Pronator Teres Muscle.

Similar cases were reported where the radial artery had a high origin and the course of the artery in the forearm was superficial [15-17]. Table 1 presents the comparison of the high origin of the radial artery with previous studies [1, 4, 9, 11, 14, 18].

The limb arteries arise by the processes of vasculogenesis and angiogenesis. By the end of stage 12 (28<sup>th</sup> day), there exists a plexus of capillaries in the limb, i.e., connected to the dorsal aorta. The capillary network enlarg-

es and differentiates in the proximo distal direction. The subclavian artery begins to differentiate by stage 13 [19].

It continues as the axial artery of the upper limb. Axillary and brachial arteries arise from the axial artery. It persists in adults as anterior interosseous artery and deep palmar arch [20]. The radial artery arises late, compared to other arteries. Initially, it arises more proximally than the ulnar artery; however, it later establishes a new connection with the main trunk at or near the level of origin of the ulnar



ANATOMICAL SCIENCES

**Figure 3.** Radial artery arising from the brachial artery in the arm

Brachial artery continues as ulnar artery BA: Brachial Artery; RA: Radial Artery; UA: Ulnar Artery; MN: Median Nerve; BR: Brachioradialis Muscle; PT: Pronator Teres Muscle.

artery. Besides, the upper portion of its original stem usually disappears. The variant radial arteries are formed due to alterations in the process of angiogenesis during the 41<sup>st</sup> to 44<sup>th</sup> days of development [21] (Figure 4).

Clinically-radial artery is often applied in procedures, such as coronary angiography, percutaneous coronary interventions, and coronary artery bypass surgery [18]. Cardiac catheterization, using the radial artery, is more effective due to its easy access for hemostasis [22]. Anatomical variation in the radial artery is a cause for the failure of the procedure [23].

The anatomic variations of the radial artery were detected as the second most frequent reason for failure rate in cardiac catheterization [23]. With the increased use of radial artery as a graft in coronary artery bypass procedures, the knowledge of variations in the radial artery is beneficial to prevent unnecessary complications [7].

The variant high originating radial artery, with the superficial course of the radial artery can be mistaken for a vein. Additionally, they can be injured during venipuncture or an orthopedic procedure [16]. These clinical implications highlight the importance of considering the various anomalies that can be expected while performing any procedure utilizing the radial artery.

## 5. Conclusion

The clinical implications of radial artery highlight the importance of considering various anomalies. Such complications can be expected in the origin and course of the radial artery while performing any procedure. The knowledge of the variations in the radial artery and a pre-operative analysis would help prevent any untoward side effects. This is especially beneficial in procedures, such as cardiac catheterization or coronary revascularization.

## Ethical Considerations

### Compliance with ethical guidelines

The study was approved by the Research and Ethics Committee of Oman Medical College, Sohar (2017-17/Sohar).

### Funding

This research did not receive any grant from funding agencies in the public, commercial, or non-profit sectors.

### Authors' contributions

Both authors equally contributed in preparing this article.

### Conflict of interest

The authors declared no conflicts of interest.

### Acknowledgments

We would like to express our thanks to Dr. Penprapa. S. Klinkachorn, Professor of Anatomy WVU, for her help in preparing and transporting the specimens and WVU for permitting the use of cadaveric material. We are grateful to Dr. Mohammad Al Shafae, Dean, COMHS, Dr. Najam Siddiqui, Head of Department of Anatomy and Neurobiology, COMHS, for their kind support. The authors also appreciate the faculty and staff of the Department of Anatomy and Neurobiology, COMHS, for their contribution to this study.

## References

- [1] Agarwal S, Lalwani R, Ramesh Babu CS. High origin of radial artery: A comparative, anatomical and embryological consideration. *International Journal of Research in Medical Sciences*. 2016; 4(8):3295-8. [DOI:10.18203/2320-6012.ijrms20162282]
- [2] Jyothsna P, Nayak SB, Mohandas Rao KG, Kumar N, Abhinitha P. High level branching and very superficial course of radial artery in the anatomical snuffbox: Its clinical and surgical implications. *OA Case Reports*. 2013; 2(7):66. [DOI:10.13172/2052-0077-2-7-728]
- [3] Gray H, Williams PL, Bannister LH. *Gray's anatomy: The anatomical basis of medicine and surgery*. 38<sup>th</sup> edition. London: Churchill Livingstone; 1995. <https://books.google.com/books?id=K24pzgEACAAJ&dq>
- [4] Nasr AY. The radial artery and its variations: Anatomical study and clinical implications. *Folia Morphologica*. 2012; 71(4):252-62. [PMID]
- [5] Rodríguez-Niedenführ M, Vázquez T, Nearn L, Ferreira B, Parkin I, Sañudo JR. Variations of the arterial pattern in the upper limb revisited: A morphological and statistical study, with a review of the literature. *Journal of Anatomy*. 2001; 199(Pt5):547-66 [DOI:10.1046/j.1469-7580.2001.19950547.x] [PMID] [PMCID]
- [6] Franchi E, Marino P, Biondi-Zoccai GG, De Luca G, Vasanelli C, Agostoni P. Transradial versus transfemoral approach for percutaneous coronary procedures. *Current Cardiology Reports*. 2009; 11(5):391-7. [DOI:10.1007/s11886-009-0054-4] [PMID]
- [7] Ostojić Z, Bulum J, Ernst A, Strozzi M, Marić-Bešić K. Frequency of radial artery anatomic variations in patients undergoing transradial heart catheterization. *Acta Clinica Croatica*. 2015; 54(1):65-72. [PMID]

- [8] Ghosh A, Chaudhury S. Unusual radial artery- A case report. *Scholarena Journal of Case Reports*. 2018; 5(2):1-4. [DOI:10.18875/2375-7043.5.205]
- [9] Kadel M, Hada S, Sedhain BP. Anatomic variation in the origin and course of radial artery: A descriptive cross-sectional study. *Journal of Nepal Medical Association*. 2019; 57(220):420-3. [DOI:10.31729/jnma.4609] [PMID] [PMCID]
- [10] Uglietta JP, Kadir S. Arteriographic study of variant arterial anatomy of the upper extremities. *Cardiovascular and Interventional Radiology*. 1989; 12(3):145-8. [DOI:10.1007/BF02577379] [PMID]
- [11] Haladaj R, Wysocki G, Dudkiewicz Z, Polgaj M, Topol M. The high origin of the radial artery (brachioradial artery): Its anatomical variations, clinical significance, and contribution to the blood supply of the hand. *BioMed Research International*. 2018; 2018:1520929. [DOI:10.1155/2018/1520929] [PMID] [PMCID]
- [12] İçten N, Süllü Y, Tuncer I. Variant high-origin radial artery: A bilateral case. *Surgical and Radiologic Anatomy*. 1996; 18(1):63-6. [DOI:10.1007/BF03207767] [PMID]
- [13] Patnaik VVG, Kalsey G, Singla K. Bifurcation of axillary artery in its 3rd part - A case report. *Journal of the Anatomical Society of India*. 2001; 50(2):166-9. [http://edge.rit.edu/content/DRIL\\_Modeling/public/Nicole\\_Varble/Articles/Anatomy/Patnaik%20\(2001\)%20Bifurcation%20of%20Axillary%20Artery.pdf](http://edge.rit.edu/content/DRIL_Modeling/public/Nicole_Varble/Articles/Anatomy/Patnaik%20(2001)%20Bifurcation%20of%20Axillary%20Artery.pdf)
- [14] Zhan D, Zhao Y, Sun J, Ling EA, Yip GW. High origin of radial arteries: A report of two rare cases. *The Scientific World Journal*. 2010; 10:1999-2002. [DOI:10.1100/tsw.2010.187] [PMID] [PMCID]
- [15] Chong CF, De Souza A. Significance of radial artery anomalies in coronary artery bypass graft surgery. *The Journal of Thoracic and Cardiovascular Surgery*. 2008; 135(6):1389-90. [DOI:10.1016/j.jtcvs.2007.11.051] [PMID]
- [16] Singh H, Gupta N, Bargotra RN, Singh NP. Higher bifurcation of brachial artery with superficial course of radial artery in forearm. *JK Science*. 2010; 12(1):39-40. <http://jkscience.org/current/Higher%20Bifurcation%20of%20Brachial%20Artery%20with%20Superficial%20Course%20of%20Radial%20Artery%20in%20Forearm.pdf>
- [17] Singh R, Malhotra R, Wadhawan M. Anomalies of radial and ulnar arteries. *Jornal Vascular Brasileiro*. 2017; 16(1):56-9. [DOI:10.1590/1677-5449.011716] [PMID] [PMCID]
- [18] Yang HJ, Gil YC, Jung WS, Lee HY. Variations of the superficial brachial artery in Korean cadavers. *Journal of Korean Medical Science*. 2008; 23(5):884-7. [DOI:10.3346/jkms.2008.23.5.884] [PMID] [PMCID]
- [19] Rodríguez-Niedenführ M, Burton GJ, Deu J, Sañudo JR. Development of the arterial pattern in the upper limb of staged human embryos: Normal development and anatomical variations. *Journal of Anatomy*. 2001; 199(Pt 4):407-17. [DOI:10.1046/j.1469-7580.2001.19940407.x] [PMID] [PMCID]
- [20] Johnson D, Ellis H, Collins P. Upper Arm. In: Standring S, Ellis H, Healy JC, Johnson D, Williams A, Collins P. editors. *Gray's Anatomy*. 39<sup>th</sup> ed. Philadelphia: Elsevier Churchill Livingstone; 2005. p. 939. [https://www.google.com/books/edition/Gray\\_s\\_Anatomy/S3jqAAAAMAAJ?hl=en](https://www.google.com/books/edition/Gray_s_Anatomy/S3jqAAAAMAAJ?hl=en)
- [21] Kumka M, Purkiss S. A rare case of unilateral variations of forearm arteries: Anatomy, embryology and clinical implications. *The Journal of the Canadian Chiropractic Association*. 2015; 59(3):253-60. [PMID] [PMCID]
- [22] Hassan AKM, Abdelmegid MAKE, Ali HH, Warda HM, Mahfouz RA, Alkhateeb AAAT. Radial artery anomalies in patients undergoing transradial coronary procedures - An Egyptian multicenter experience. *The Egyptian Heart Journal*. 2016; 68(1):31-6. [DOI:10.1016/j.ehj.2015.07.001]
- [23] Zheng Y, Shao L, Mao JY. Bilaterally symmetrical congenital absence of radial artery: A case report. *BMC Surgery*. 2014; 14:15. [DOI:10.1186/1471-2482-14-15]

---

This Page Intentionally Left Blank

---