

Lectin Histochemical Study of GalNac and GlcNac Containing Glycoconjugates in Colon Adenocarcinoma

Mohamad Reza Arab^{1*}, Ali Reza Rojhan², Mehdi Jahantigh³, Mehdi Mohammadi⁴

1. Professor of Histology, Department of Anatomical Sciences, School of Medicine, Cell and Molecular Research Center, Zahedan University of Medical Sciences, Zahedan, Iran.

2. M Sc in Anatomical Sciences, School of Medicine, Zahedan University of Medical Sciences, Zahedan, Iran.

3. Assistant Professor of Pathology, Department of Pathology, School of Medicine, Cell and Molecular Research Center, Zahedan University of Medical Sciences, Zahedan, Iran.

4. Assistant Professor of Biostatistics, Department of Biostatistics, School of Medicine, Health Promotion Center, Zahedan University of Medical Sciences, Zahedan, Iran.



Mohammad Reza Arab is a member of anatomical sciences department in medical school in Zahedan University of Medical Sciences. His Research work focuses on lectin histochemistry in embryonic tissues and neoplasms, especially in cancer of gastrointestinal tract to find aberrant glycosylation of cell surface glycoconjugates. He also is working in occupational health lab to determine histopathological changes of organs tissues after inhalation of toxic fumes generating in welding process and organic solvents.

Article info:

Received: 17 Jul 2013

Accepted: 4 Oct 2013

Key Words:

Colon,
Adenocarcinoma,
Glycoconjugates,
GalNac, GlcNac.

ABSTRACT

Introduction: Alteration of terminal sugars of Glycoconjugates is one of the important aspects of neoplasia. The aim of the present study was to identify GalNac and GlcNac containing glycoconjugates in different grades of neoplastic cells in adenocarcinoma of colon.

Methods: Histological sections prepared from paraffin blocks belong to 30 patient of colon adenocarcinoma obtained from Khatam-Al-Anbia hospital in Zahedan, Iran and stained by H-E, PAS, WGA and SBA/Alcian blue lectins. Histologic slides were graded histochemically (0-3) according to staining intensity, and collected data were analyzed by SPSS software.

Results: Statistical analysis showed only a significant difference in staining intensity for SBA lectin ($P < 0.001$). Furthermore with increasing the histopathological grades, the frequency of positivity of neoplastic cells for GalNac and GluNac was also increased.

Conclusion: The pattern of staining of neoplastic cells to WGA and SBA lectins were changed with increasing of histopathological grades.

1. Introduction

A

denocarcinoma of the colon which comprises up to 95% of colon malignancies is a worldwide disease and unfortunately have high mortality rate due to cancer of gastrointestinal tract [1]. Colon

carcinoma is the second most common cause of cancer death. The prognosis of patients with colon cancer and distant metastasis is very low [2]. Three histological grades of colon adenocarcinoma were defined according to histological criteria of tumor cells such as glandular formation, nuclear atypia, hyperchromasia and the rate of mitotic figures, were defined as well differentiated,

* Corresponding Author:

MR Arab, PhD

Address: Professor of Histology, Department of Anatomical Sciences, School of Medicine, Cell and Molecular Research center, Zahedan University of Medical Sciences, Zahedan, Iran.

Tel: +98541-2414352

E-mail: mr_arabz@yahoo.com

moderately differentiated and poorly differentiated adenocarcinoma [1]. One of the most important aspects of biological behavior of cancer cells is formation of metastasis in organs other than origin. The ability of cancer cells to metastasize is a multistep phenomenon which involves a series of events including loosening, adhesion, signaling and invasion to blood and lymphatic vessels, survival in circulation and growth at a distant location [3-4]. The formation of the distant metastasis remains as a long problem in treatment of patients suffering from cancer. Metastasis of cancer cells is very similar to the adhesion of leukocytes to endothelium and migration out of the blood and lymphatic vascular system in normal physiological or pathological conditions [3]. Studies showed that changes in terminal carbohydrate or glycocalyx of glycoproteins and glycolipids on the cell surface of cancer cells have been directly correlated with the formation of distant metastasis [5].

Cell surface glycoconjugates are a class of glycoproteins and glycolipids which cover the outer surface of all mammalian cells. The quantity and quality of these terminal sugars coat of glycoconjugates are known to play an important role in cell-cell and cell-extracellular matrix interactions, cell-cell recognition, communication, differentiation, embryogenesis, tumorigenesis, tumor progression and metastasis [6-7]. It seems that physical, chemical, structural diversity and biological properties of cell surface glycoconjugates is largely dependent on its carbohydrate composition [8]. Glycosylation pattern of cell surface and extracellular matrix glycoproteins and glycolipids largely determine the behavior of cells in normal and pathologic conditions [3]. Lectins are a group of specific nonimmunogenic proteins or glycoproteins of plant or animal origin that binds to terminal sugars of cell surface glycoconjugate with high affinity and specificity. These properties of lectins make them as differentiating biological markers to study cancer cells and metastatic cell lines [9-10]. Alteration of glycan residue of glycoconjugates in cancer associ-

ated mucin is an important factor in tumor growth and uncontrolled proliferation of cancer cells [11]. Wheat germ agglutinin (WGA) and soya bean agglutinin (SBA) which is widely used in tumor pathology research, detect N-acetylglucosamine (GlcNac) and N-acetylgalactosamine (GalNac) residue, respectively. The aim of the present study was to identify GalNac and GlcNac containing glycoconjugate in different grades of colon adenocarcinoma.

2. Materials and Methods

Histological sections prepared from paraffin blocks belonged to 30 patient of colon carcinoma (each grade 10 patient) obtained from pathology file of Khatam-Al-Anbia hospital in Zahedan Iran, and were stained by Hematoxylin-Eosin (H-E), Periodic Acid Schiff (PAS), Alcian Blue pH=2.5, SBA and WGA (SIGMA) lectins. The sections were graded histopathologically (well, moderately and poorly differentiated adenocarcinoma) and histochemically according to staining intensity (0= No staining, 1= mild staining, 2= moderate staining, 3=severe staining). For lectin histochemistry, sections were deparaffinized, rehydrated and incubated for 2 hours with lectins WGA and SBA in humidified chamber in room temperature. Lectins were diluted up to 5 µg/ml in PBS pH=6.8 [12]. Thereafter, sections were immersed for 30 minute in a 0.03% solution of diaminobenzidine [(DAB), Sigma] as chromogen which contained 0.1% H₂O₂, then sections were carefully rinsed for 30 minutes with tap water and counterstained with Alcian blue pH=2.5 up to 5 minute. Sections were dehydrated, cleared and coverslipped. Parallel control sections were used for each patient who was undergoing the same treatment protocol except for those who was incubated with lectin or DAB solution. Histochemical grading was done blindly.

Collected data for mean of staining intensity was analyzed by non-parametric test of Kruskal Wallis and Mann Whitney. The frequencies of positivity of neoplastic cells

Table 1. Comparison of staining intensity of neoplastic cells according for GalNac & GlcNac containing glycoconjugates

Lectins Histopathological Grades	Soya Bean Agglutinin (SBA)	Wheat Germ Agglutinin (WGA)
Well Differentiated	0	2.17 ± 0.3
Moderately Differentiated	1.42 ± 1*	2.04 ± 0.2
Poorly Differentiated	1.57 ± 0.7**	1.9 ± 0.8

*Denotes significant difference between well and moderately carcinoma (p<0.001).

** Denotes significant difference between moderately and poorly carcinoma (p<0.001).

ANATOMICAL SCIENCES

Table 2. Frequency percent of cells of colon adenocarcinoma according to staining intensity to WGA and SBA lectins for GlcNac and GalNac bearing glycoconjugates.

Histochemical Grades Histopathological Grades	NO STAINING WGA, SBA		Mild Staining WGA, SBA		Moderate Staining WGA, SBA		Severe Staining WGA, SBA	
	Well Differentiated	7.89	100	21.26	0	24.8	0	46.05
Moderately Differentiated	11.31	19.65	20.7	13.74	24.1	27.63	43.8	38.98
Poorly Differentiated	16.6	25.83	10.83	14.7	22.1	25.8	50.47	34.74

ANATOMICAL SCIENCES

in each histochemical grade were measured for all of patients.

3. Results

Statistical analysis of obtained data for mean of staining intensity of neoplastic cells for GalNac containing glycoconjugates in different histopathological grade, showed that there was a significant difference between all histopathological grades (Kruskal Wallis $p < 0.001$). Furthermore, analysis by Mann Whitney test showed that there is significant difference for mean of staining intensity between well differentiated colonic adenocarcinoma with moderately ($p < 0.001$) and poorly differentiated adenocarcinoma ($p < 0.001$). There was no significant difference between all histopathologic grades for mean of staining intensity for WGA lectin (GlcNac) between neoplastic cells of colonic adenocarcinoma (Table1).

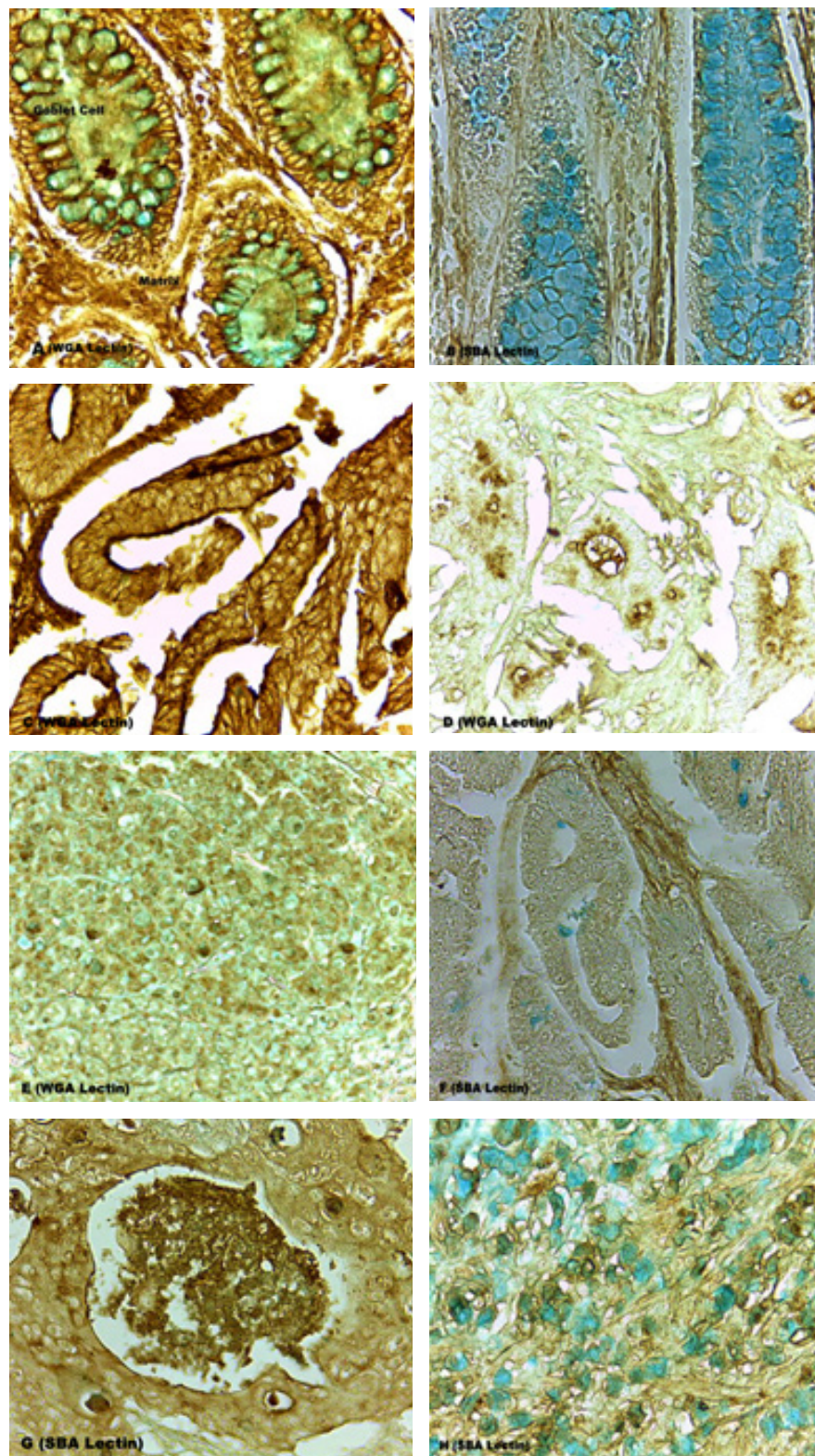
Distribution of neoplastic cells according to the degree of staining intensity showed that with increasing the histopathological grade, the frequency of cell positivity for GalNac and GlcNac containing glycoconjugates were also increased (Table2). Distribution of GalNac and GlcNac containing glycoconjugates in neoplastic cells showed that in different histopathologic grade, the pattern of reaction of cells varies from plasmalemma to cytoplasm and extracellular matrix. This pattern of reaction varies from diffuse to granular staining in different histopathological grades in plasmalemma, supranuclear or infranuclear and extracellular matrix (Figure 1. A-H).

4. Discussion

Our results showed that the nature and the extent of terminal sugars of cell surface glycoconjugate were modified in cancer cells of colonic adenocarcinoma.

The degree of reactivity of tumor cells for GlcNac bearing glycoconjugate were decreased from well to poorly differentiated adenocarcinoma, although the reaction of cancer cells for GalNac containing glycoconjugates were increased from well to poorly differentiated adenocarcinoma. Different behavior of cancer cells in colon adenocarcinoma may lead to the changes of glycoconjugates which take place in the process of neoplastic formation. Although the exact modification of glycosylation pattern in colon cancer is unknown yet, but it seems that abnormal glycosylation of proteins as an important post translation modification in cancer may lead to synthesis of abnormal glycoconjugates in cell surface, cytoplasm or extracellular matrix that causes invasive properties for malignant cells [13]. Our results in different staining properties of colonic cancer cells are in accordance with Brooks et al study on breast cancer, colorectal carcinoma and lung adenocarcinoma [14-16]. Changes in cellular glycosylation alter cell behavior in both normal and malignant cells. There is a good correlation between the degree of Helix Pomatia Agglutinin (HPA) positivity and prognosis for patient suffering from breast cancer [15]. Studies showed that GalNac residue detected by HPA might be resulted from the failure of sialylation mechanism during post translation modification [15]. More than half of the eukaryotic proteins are glycoprotein and about 90% of these glycoproteins are N-linked in which the sugar moiety is attached to the amide group of an asparagin in the consensus sequence Asn-X-Thr, where X is any residue except prolin [3-17].

The changes of extracellular matrix components reported in this study may be attributable to the modifications of secreted mucus. Mucins are large extracellular proteins which heavily glycosylated. Oligosaccharides of these glycoproteins predominantly are of O-linked type. There is substantial evidence showing that alteration in mucin expression or in glycosylation machinery



ANATOMICAL SCIENCES

Figure 1. The reaction of Goblet cells and extracellular matrix in crypt of Lieberkuhn to WGA (A) and SBA (B) lectins and Alcian blue was shown. Magnification, $\times 40$, $\times 10$. The Positivity of neoplastic cells in well (C), moderately (D) and poorly (E) differentiated adenocarcinoma for GlcNac containing glycoconjugates with decreasing histochemical grade was shown. Magnification $\times 40$. The increasing positivity of neoplastic cells in well (F), moderately (G) and poorly (H) differentiated adenocarcinoma for GalNac containing glycoconjugates with increasing histochemical grade was shown. Magnification, $\times 40$.

leads to development of cancer and also influences the growth differentiation, transformation, invasion and metastasis [17-18]. It seems that terminal sugars of cell surface and extracellular matrix glycoconjugates are greatly modified in cancer cells. However, further works are required to clarify the biological roles of these saccharides in tumorigenesis and metastasis.

Acknowledgement

This research is financially supported by the Deputy for research of Zahedan University of Medical Sciences, and authors would like to gratitude hi The result of this article is obtained from the research proposal no. 91/2482 issued by Zahedan University of Medical Sciences, Iran. .

References

1. Kumar V, Abbas A, Fausto N, Mitchell R. Robbins basic pathology. 8th ed. Saunders, Philadelphia, 2007, 619-624
2. Kohler S, Ullrich S, Richter U, Schumacher U. E-/p- Selectins and colon carcinoma metastasis: first in vivo evidence for their crucial role in a clinically relevant model of spontaneous metastasis formation in the lung. *British Journal of Cancer* 2010; (102) : 602-609.
3. Wang PH. Altered Glycosylation in cancer: Sialic acids and sialyltransferases. *Journal of Cancer Molecules* 2005; 1 (2) : 73-81.
4. Schumacher U, Adam E. Lectin Histochemical HPA-binding pattern of human and colon cancer is associated with metastases formation in severe combined immunodeficient mice. *Histochemical Journal* 1997; (29) : 677-684.
5. Lascar J, Sanchez Jf, Audfrag A, Coll JI, Breton C, Mitchell Ep, et al. Structural basis for recognition of breast and colon cancer epitopes Tn antigen and Forssmann disaccharide by helix pomatia lectin. *Glycobiology* 2007; (17) : 1077-1083.
6. XC Xu, Brink U, Schauer A, Gabius Hj. Differential binding activities of lectins and neoglycoproteins in human testicular tumors. *Urology Research* 2000; (28) : 62-68.
7. Thies A, Moll I, Berger G, Schumacher U. Lectin binding to cutaneous malignant melanoma: HPA is associated with metastasis formation. *Br J Cancer* 2001; 84 (6) : 819-823.
8. Davis B.G. Recent development in glycoconjugates. *Journal of chemistry Soc. Perkin Transactions* 1999; (1) : 3215-3237.
9. Krogerus L, Andersson LC. Different lectin-binding patterns in primary breast cancers and their metastases. *Cancer* 1990; 66: 1082-1809.
10. Sherwani AF, S Mahmood, F Khan, Rh Khan. Characterization of lectins and their specificity an carcinoma an appraisal. *India Journal of Clinical Biochemistry* 2003; 18 (2) : 169-180
11. Sandra VG, Zlocowski N, Nores GA, Irazoqui FJ. Anti-idiotypic antibody mimicking a T-antigen-specific lectin inhibits human epithelial tumor cell proliferation. *Immunology and Cell Biology* 2010; (88) : 787-794.
12. Arab M.R, Salari S, Karimi M, Mofidpur H. Lectin histochemical study of cell surface glycoconjugate in gastric carcinoma using Helix Pomatia Agglutinin. *Acta Medica Iranica* 2010; 88 (4) : 209-213.
13. Fukotomi T, Hirohashi S, Nanasawa T, Yamomomto H. The prognostic value of tumor associated carbohydrate structure correlated with gene amplification in human breast carcinoma. *Japnian Journal of Surgery* 1991; 21 (5) : 499-507.
14. Laack E, Nikbackt H, peters A, kugler C, Jasiewicz Y, Edler L. Lectin histochemistry of resected adenocarcinoma of the lung. Helix pomatia agglutinin binding is an independent prognostic factor. *American Journal of Pathology* 2002; (160) : 1001-1008.
15. Brooks SA, Hall DMS, Buley I. GalNac Glycoprotein expression by breast cell lines, primary breast cancer and normal breast epithelial membrane. *British Journal of Cancer* 2001; 85 (7) : 1014-1022.
16. Ikeda Y, Mori M, Adachi Y, Matsushima T, Sugimach K. Prognostic value of the histochemical expression of HPA in advanced colorectal cancer. *Diseases of the Colon and Rectum* 1994; 37: 181-184.
17. Kaleem A, Khurshid A, Ahmad I, Walker-nasir E, khan S, Choudhary I, et al. Terminal galactose as cancer recognition marker: computing analysis with implication of vicinal sugars, linkage and anomery. *Pakistan Journal of Zool* 2008; 40 (2) : 135-143.
18. Schomacher U, Mukhtar D, Stehling P. Is the lectin binding pattern of human breast and colon cancer cells influenced by modulators of sialic acid metabolism. *Histochemical Cell Biology* 1996; (106) : 599-604.