

# Effects of Date Palm (*Phoenix Dactylifera*) Gemmule Extract on Morphometric Parameters of Reproductive Tissues, Hormones and Sperm Quality in Rat

Soghra Bahmanpour<sup>1\*</sup>, Ferydoon Kavoozi<sup>2</sup>, Tahereh Talaei<sup>3</sup>, Mohammad Reza Panjehshahin<sup>4</sup>

1. Anatomy Department, Shiraz University of Medical Sciences (SUMS), Shiraz, Iran.

2. Anatomy Department, Shiraz University of Medical Sciences, Shiraz, Iran.

3. Anatomy Department, Shiraz University of Medical Sciences, Shiraz, Iran.

4. Pharmacology Department, Shiraz University of Medical Sciences, Shiraz, Iran.



Professor **Bahmanpour** is a member of the Anatomy Department in Shiraz University of medical Sciences. She specializes in Reproductive biological sciences including the searching for male and female's factor infertility causes and improving the reproductive and gametes defects by administrating herbal and chemicals remedies. She is working with embryonic Stem cells (ESc) in Stem cell Lab of Anatomy Department recently. She is trying to differentiate ESc towards gamete and germ-like cells and oocyte in vitro development.

Article info:

Received: 13 Dec 2012

Accepted: 1 Mar 2013

## Key Words:

Phoenix Dactylifera Gemmule,  
Spermatogenesis,  
Testis,  
Hormones,  
Sperm Quality.

## ABSTRACT

**Introduction:** Date palm gemmule has been used in traditional medicine to improve the semen quality and treat infertility. Their components remedies those are rich of antioxidant and vitamins can influence spermatogenesis. The aim of this project was to evaluate the effects of date palm gommule water/alcoholic extract on reproductive tissues, sex hormone and sperm quality of rat.

**Methods:** Seventy male rats were divided into 7 groups. Five experimental groups were treated with zero, 50, 100, 150 and 200mg/kg/body weight of date palm gemmule water/alcoholic extract for 50 days. The controls was injected either busulfan or solvent. At the end of the experiment, blood samples were taken to perform hormone assay. The sperm samples were collected and count. The sperm motility and morphology were also measured. The smears were prepared and stained with acridin orange, aniline blue, eosin and chromycin A3. Morphometrical analyses were performed to measure the seminiferous tubule diameter and the thickness of epithelium of ductus deferens and epididymis.

**Results:** The results indicated estradiol decreased significantly in the group was fed with 50 mg/kg/body weight per day and testosterone decrease in the groups treated with 100 and 150 mg/kg/day of extract. The percent of the sperm with good morphology and normal chromatin histone were increased significantly in a non-linear way ( $P < 0.05$ ). The extract also significantly ( $P < 0.05$ ) increased in seminiferous tubule diameter and epididymis epithelium thickness.

**Conclusion:** In conclusion the components of extract improve the sperm chromatin quality as indicated by aniline blue staining and also the testis morphology and spermatogenesis as indicated by morphometric measurements and Johnson scoring technique respectively. Finally the results showed that the high dose of the extract showed the best protective effects against busulfan toxicity without decreasing in testosterone concentration in comparison to the other treated groups."

\* Corresponding Author:

Soghra Bahmanpour, PhD

Anatomy Department, Shiraz University of Medical Sciences (SUMS), Shiraz, Iran.

Tel: 0098 711 2304372 / Fax: 0098 711 2304372

E-mail: bahmans@sums.ac.ir

## 1. Introduction

**T**hirtieth to fiftieth percent of couples are suffering from infertility [1]. Infertility is a major health problem. Treatment of infertility has been encountered with a lot of medical progression; however, the procedure varies depending largely on the approach availability in different country [2]. Therefore, it is essential to find non-invasive and natural methods to treat the male infertility. The use of the herbal remedies and their extraction are important customary methods.

For many years, it is believed a significant number of germ cell precursors do not mature and differentiate into the spermatozoa during spermatogenesis. Besides, several pathological processes can accelerate the loss of germ cells from the seminiferous epithelium [3]. Disorders characterized by poor semen quality can be reflected by seminiferous tubule failure [4].

Taking some remedies or adding them to the semen samples may improve sperm quality and it helps fertility in subfertile men. Red palm oil [5] and palm date pollen [6] has been reported to influence sperm parameters in rats. Palm date gemmule (*Phoenix dactylifera*) is one of remedies has been well known since ancient times and it was considered by the Egyptians as being a fertility symbol. In Iranian traditional medicine, it used to treat impotent. Thirteen flavonoid, as its ingredients were identified by liquid chromatography-electrospray ionization-tandem mass spectrometry [7]. It is a good source of natural antioxidants [8]. Flavenoid is the major class of phytoestrogen. It is functionally and structurally similar to estrogen [9] that affects spermatogenesis. Flovonoids also act as antioxidant [10]. Antioxidants can also protect testis [11, 12]. This component also protects sperm and is associated with semen quality as well [13]. The date palm gemmule with flavenoid content acts as antioxidant and sex hormon regulator. There is lack of evidence on the effects of date palm gemmule on spermatogenesis. Regards to these considerations, the objectives of this study were to determine the impacts of date palm gemmule supplementation on histopathological structure and hormone concentration of male reproductive tissues and sperm quality.

## 2. Materials & Methods

### 2.1. Animals

Seventy Spargue Dawley male rats (weighted 250-300 g and aged more than two months old) were selected and

divided into 7 groups randomly. All rats acclimated to the lab condition for one week. They maintained under the standard condition (22°C, 12 h dark and 12 h light). Five groups were injected with single dose of 5 mg/kg/body weight of busulfan intraperitoneally to induce partial sterility [14]. Two groups were not injected with busulfan and mentioned as controls.

### 2.2. Extract Preparation

Date palm gemmule extract were obtained through percolation methods. Fresh gemmules were obtained from *P. dactylifera* (Shahani) that grew in Jahrom, Fars, Iran and maintained in herbarium of Shiraz University with voucher number 40010. To obtain the water/alcohol extract, 150 g of date palm gemmule was grated and added 700 mL of 50% ethanol. The suspension was percolated for 72 hours. The solvent was dried under a vacuum. The final yield was 13.5 g dried powder [15,16]

### 2.3. Animal Feeding

Busulfan treated-groups were fed with 50, 100, 150 and 200 mg/kg/body weight per day of the extract respectively (G1-G4) a day after busulfan injection. The animal were fed the extract by gavage technique using a feeding needle. Feeding was been continuing for 50 days. The doses were chosen according to the study that was performed by Pritchett [17]. The fifth group (G5) was received only busulfan (Sham), the sixth group (G6) was treated with distilled water (Solvent) (negative control) and the seventh group (G7) had no treatment (non-treated control).

### 2.4. Blood Sampling

All experiments were performed in accordance with our center's guidelines for the ethical handling of animals. After fifty days at the end of experiment, the rats were anesthetized and blood samples were taken from abdominal aorta. Blood samples were centrifuged and their plasma was separated for measurement of hormones. The testosterone and estradiol plasma concentration were assessed by radioimmunoassay (RIA) kit, (Spectra, Finland) according to manufacturer's instruction

### 2.5. Sperm Sampling

Sperm samples were collected by cutting one centimeter of the cauda of the right ductus deferens. The piece of the ductus deferens was put in the Hank's balanced salt solution (HBSS) for 5 min. The sperms were swim into the HBSS. The number of the sperms was counted using

a hemocytometer slide [18]. A smear was prepared from each sample and selected ten field of the microscope slide assessed the sperm morphology randomly. The pattern of sperm motility in each field was observed [18].

## 2.6. Sperm Chromatin Assay

Sperm smears were stained with acridin orange (to assay DNA denaturation), aniline blue (to assay histone content of the sperm head) and chromomycin A3 (to assay protamine content of the sperm head). To evaluate the sperm morphology, the smears stained with eosin as follow:

Acridine Orange(AO) (BDH,ChemicalLtd, Poole ,England) tests assessed the DNA integrity or denaturation. The specimens were fixed with acetic alcohol, then stained and examined with a fluorescence microscope (Nikon,E800, Japan). AO intercalated with double-stranded DNA emits green fluorescence and single-stranded DNA emits red fluorescence. The percentage of the sperm nuclei with green and red colors were recorded and sperm with DNA denaturation was evaluated [19].

Aniline blue (Merck,Darmstadt,Germany) staining was used to assess the sperm nucleus histone.The smears were fixed with glutaraldehyde and stained with aniline blue.

The sperms with extra histone showed different colors after staining. The sperm with light blue were recorded as normal histone and those with dark blue were the extra histone and abnormal ones. The percentage of the intensity of different sperm colors was recorded for each sample [20].

ChromomycineA3 (CMA3) (Merck, Darm-15stadt, Germany) is used for the degree of protamine of the mature sperm.The smears were fixed with Carnoy and were

stained with CMA3 solution in McElvin buffer [21]. The bright immature sperm was indicated as CMA3positive and non-bright and mature sperm was the CMA3 negative sperm. For each sample, the percentage of CMA3 negative and positive has been recorded.

## 2.7. Histological Studies

In the day fifty, all rats were killed under deep anesthesia and the reproductive tissues were removed, weighed, fixed and processed histologically. The specimens were sectioned and stained with H&E. The sections were study under the light microscope. Spermatogenesis was assessed by the Johnsen scoring technique [22]. The thickness of the epididymis epithelium, ductus deferens epithelium and the seminiferous tubule diameter were measured by a light microscope equipped by a calibrated eye piece.

## 2.8. Statistical Analyses

The data were analysis by analysis of variance (ANOVA), Tukey and Kruscal-Wallis tests. All statistical analyses were done with SPSS v. 11.5 software for Windows and the data were graphed with Excel. A p value less than 0.05 considered as significant difference.

## 3. Results

### 3.1. Hormones Assay

Low dose (50 mg/kg) of the extract in the diet of the rats decreased in estradiol concentration in plasma significantly compared to the sham and negative control groups ( $P<0.05$ ). Administration of 100 and 150 mg/kg of the extract showed a significant decrease in testosterone concentration in plasma compared to non-treated control. The data summarized in table 1.

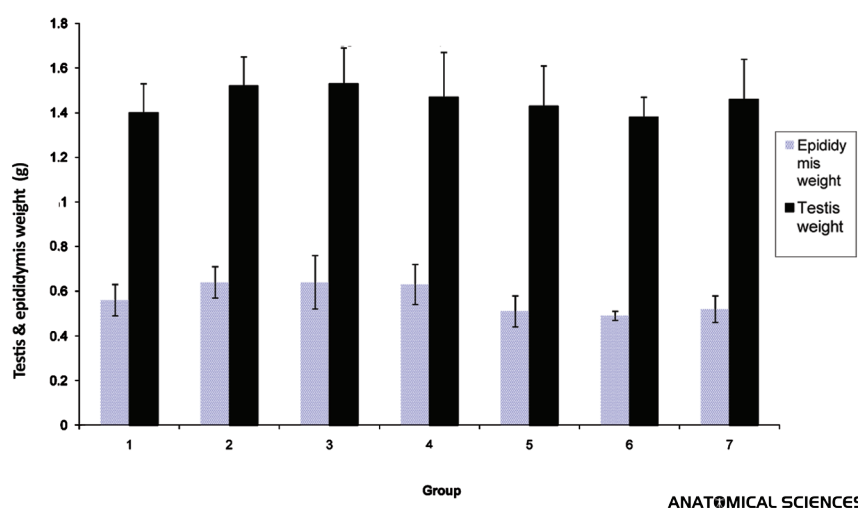
**Table 1.** Effects of date palm gemmule on hormone levels and sperm count in different group of rats (n=10)

Group	Estradiol pg/mL	Testosteron ng/mL	Count (10 <sup>6</sup> )
G1( 50mg/kg + busulfan)	10.47± 4.67¥	2.18± 0.84	3.502677.54 ± 1.015
G2 (100 mg/kg + busulfan)	14.11± 4.28	2.15 ± 1.31*	7.630803.80 ± 7.87
G3 (150mg/kg + busulfan)	17.34 ±4.45	1.84 ±0.65*	6.721279.28 ± 1.15
G4 (200mg/kg + busulfan)	18.75± 3.70	3.02± 1.61	4.745172.98 ± 1.60
G5( Busulfan)	20.61± 4.43	2.18± 1.20	5.92475551.35 ± 9.18
G6( Distilled water)	18.98± 4.29	5.52± 3.36	4.795831.52 ± 1.05
G7 (Non-treated)	14.37 ±2.23	5.57 ± 4	7.143616/03± 1.4

\* Significant Difference with control groups ( $P<0.05$ ).

¥ Significant Difference with control groups ( $P<0.05$ ).

ANATOMICAL SCIENCES



**Figure 1.** Effects of date palm gemmul on testis and epididymis weight of different groups

### 3.2. Effects of the Extract on Weight

The mean of the body weight increased significantly after feeding the animals with the extract compared to the mean of the body weight at the beginning of the treatment. The mean of the testes weight was not different after feeding with the extract compared to the control groups. Administration of the 100, 200 and 150 mg/kg of the extract showed a significant increased in epididymis weight compared to the sham group (Fig 1).

### 3.3. Effects of the Extract on Sperm Parameters

Staining the sperms with eosin showed a significant increase in the mean of the percentage of the sperms with normal morphology in 100, 150 and 200 mg/kg treated-animals the compared to the negative control. The sperm count did not change significantly after extract administration (Table 1 and 2).

**Table 2.** Effects of date palm gemmule on sperm chromatin in different group of rats (n=10)

Group	Percentage of normal morphology (%)	Protamine content/ CMA3 staining (%)	Histone content/ Aniline blue staining (%)	Acridine orange staining DNA double strand (%)
G1( 50mg/kg + busulfan)	95.14±2.73	100± 0	100± 0+	100± 0
G2 (100 mg/kg + busulfan)	95.28±2.36*	100± 0	100± 0+	100± 0
G3 (150mg/kg + busulfan)	95.33±1.93*	100± 0	100± 0+	100± 0
G4 (200mg/kg + busulfan)	96.14±3.02*	100± 0	100± 0+	100± 0
G5( Busulfan)	91.30±3.4	100± 0	97.20±0.91	100± 0
G6( Distilled water)	94.14 ±1.46	100± 0	98.28 ±1.38	100± 0
G7 (Non-treated)	94.50±2.67	99.66±0.70	97.25± 1.16	100± 0

\*Significant difference with busulfan-treated group (P<0.05)

+ Significant difference with control groups (P<0.05)

ANATOMICAL SCIENCES

### 3.4. Effects of the Extract on Sperm Chromatin Quality

Acridin orange and chromycin A3 assays showed the percentage of sperms with normal DNA and protamine

content did not change significantly after feeding the rats with the extract. However, administration of the extract (all doses) increased the percentage of the sperms with normal histone content compared to the sham, negative or non-treated control (Table 2).

**Table 3.** Effects of date palm gummule on morphometric parameter of reproductive tissue and Johnson's Scoring in different group of rat (n=10)

Group	Ductus deferens epithelium thickness (μm)	Seminiferous tubules Diameters (μm)	Epididymis epithelium thickness (μm)	Johnson's Scoring
G1( 50mg/kg + busulfan)	3.45 ± 0.11	17.35 ± 0.54¥	2.3 ± 0.04	9.8 ± 0.05
G2 (100 mg/kg + busulfan)	3.58 ± 0.18	17.98 ± 0.33¥	2.33 ± 0.07	9.9 ± 0.03
G3 (150mg/kg + busulfan)	3.15 ± 0.16	17.98 ± 0.31¥	2.31 ± 0.04	9.86 ± 0.02
G4 (200mg/kg + busulfan)	3.61 ± 0.1	17.34 ± 0.17¥	2.38 ± 0.04	9.94 ± 0.02
G5( Busulfan)	3.13 ± 0.24	15.78 ± 0.39	1.71 ± 0.01+	9.41 ± 0.05
G6( Distilled water)	3.75 ± 0.22	17.68 ± 0.2*	2.22 ± 0.05	9.95 ± 0.02
G7 (Non-treated)	3.65 ± 0.1	21.78 ± 0.44	2.2 ± 0.05	9.95 ± 0.02

\*Significant difference with non-treated control(P&lt;0.05)

¥ Significant difference with busulfan-treated group (P&lt;0.05)

+ Significant difference with all other groups (P&lt;0.05)/

ANATOMICAL SCIENCES

### 3.5. Hisopathological Study

Histological studies showed a slightly disturbed in spermatogenesis according to Johnsen scoring system in sham animals. Normal spermatogenesis was observed in all experimental groups that fed with the extract (Table 3). The statistical analyses revealed a significant improvement in the spermatogenesis in experimental groups compared to the sham groups.

### 3.6. Morphometric Study

Morphometric studies showed busulfan decrease seminiferous tubules diameter significantly compared to the seminiferous tubules of non-treated group. Administration of the extract led to a significant increase in the seminiferous diameter compared to those of busulfan-treated group (P<0.05). In busulfan-treated rats, the thickness of the epididymis epithelium was showed a significant decrease compared to those of control rats. In extract-treated rats, the thickness of the epithelium increased significantly compared to those of busulfan-treated group. There was no significant difference in the thickness of ductus deferens epithelium.

Histological structure of ductus deferens, epididymidis, seminal vesicle and prostate were normal in all groups.

## 4. Discussion

The beneficial nutritional value of date palm( Phoenix dactylifera) on health of human and animal have been

claimed. Extract of date pollen increased the sperm count in rat ® and enhanced spermatogenesis, testosterone concentration and sperm chromatin quality.

Phoenix dactylifera contains minerals [23], flavonoid, glycosides [7], vitamins A and C, proteins and carbohydrates [24]. These contents may influence various biological effects on spermatogenesis. Flavonoids can act as agonist or antagonist of the estrogen [25-27] . There is a controversy in the effects of phytoestrogens in sperm quality. Some reports revealed no effects on spermatogenesis and the others showed a dose dependent decrease on sperm count [28-31]. The research showed the extract from plants such as kiwi contain flavonoids led to a decrease in testosterone level [32]. On the other hand, cartamus extract, another flavonoid containing plant, increase testosterone level. The flavonoids can interrupt hypophysial/gonadal axis and by this way influence testosterone level and also spermatogenesis. Date palm gummule with its hormonal interrupters may change the hypophyseal/gonadal axis and by this way impact on testosterone. Despite of reduction in testosterone level, date palm gummule did not impact on sperm count. The extract led to an increase in epididymidis weight. Estrogen can regulated the absorption of the fluid in epididymidis. Estrogenic effect of the flavonoid may dilute the sperm count in epididymidis by prevention of fluid absorption [33]. Therefore, in spite of minimal change in sperm count after extract administration, the epididymis weight gain was occurred.



Date palm gemmule may exert its effect on spermatogenesis by vitamins content. Dates contain at least six vitamins including a small amount of vitamin C, and vitamins B1 (thiamine), B2 (riboflavin), nicotinic acid (niacin) and vitamin A [24]. Vitamin C is one of the antioxidants that present in the semen and use as ROS scavenger in vitro and in vivo [34-36]. Flavonoids are also ROS scavenger as well. The antioxidative effect is mainly due to phenolic components, such as flavonoids [37], phenolic acids, and phenolic diterpenes. The antioxidant activity of phenolic compounds is a result of their redox properties, which can play an important role in absorbing and neutralizing free radicals, quenching singlet and triplet oxygen, or decomposing peroxides [38]. Recent studies indicate that the aqueous extracts of dates have potent antioxidant activity [8]. A negative correlation has been shown between the ROS concentration and spermatogenesis [39]. The presence of the antioxidant such as vitamin C, A and also flavonoids in date palm gemmule extract may have a protective role in spermatogenesis.

The presence of vitamin A for the normal progression of male germ cell differentiation has been known for many years [40]. Vitamin A has been demonstrated to improve nucleoprotein change during spermiogenesis [41]. Our data suggested a decrease in the percentage of the sperm with normal histone content. Palm gemmule can improve histone exchange during protamination. Sperm morphology can be improved by intraperitoneal injection of vitamin C [42]. Our data also indicate improvement in sperm morphology and chromatin quality by feeding the animal with the extract.

Date palm has protective effects on induced hepatotoxic liver in rat [43]. The vitamin C content of the date palm also protects the liver against toxins [24]. In the same way, the date palm contents may protect the seminiferous tubules against busulfan toxicity as indicated by Johnstone scoring system.

In conclusion, the date palm gemmule extract can improve the spermatogenesis. The high dose of the extract showed the best protective effects against busulfan toxicity without decreasing in testosterone concentration in comparison to the other treated groups. However, the exact mechanism of the effect is unknown and need more investigation.

## Acknowledgment

The authors wish to thank the research deputy of Shiraz University of Medical Science for offering the grant and Mr. Masoodi for technical support.

## References

1. Sadler SW. Langman's medical embryology. 11th edition. Lippincott Williams & Wilkins, Philadelphia, 2010: pp 41.
2. Adashi EY, Cohen J, Hamberger L, Jones HW Jr, de Kretser DM, Lunenfeld B. Public perception on infertility and its treatment: an international survey. The Bertarelli Foundation Scientific Board. Hum Reprod. 2000; 15:330-4.
3. De Kretser DM, Baker HW. Infertility in men: recent advances and continuing controversies. J Clin Endocrinol Metab. 1999; 84:3443-50.
4. McLachlan RI, de Kretser DM. Male infertility: the case for continued research. Med J. 2001; 174:116-7.
5. Aboua YG, du Plessis SS, Reichgelt P, Brooks N. The in vitro effects of superoxide, some commercially available antioxidants and red palm oil on sperm motility. Asian J Androl. 2009; 11:695-702.
6. Bahmanpour S, talaei T, Vojdani Z, Panjehshahin MR, Poostpasan A, Zareei S et al. effect of Phoenix Dactylifera pollen on sperm parameters and reproductive system of adult male rats. Iranian Journal of medical sciences. 2006; 31: 208-212.
7. Hong YJ, Tomas-Barberan FA, Kader AA, Mitchell AE. The Flavonoid Glycosides and Procyanidin Composition of Deglet Noor Dates (Phoenix dactylifera). J Agric Food Chem. 2006; 54:2405-11.
8. Al-Farsi M, Alasalvar C, Morris A, Baron M, Shahidi F. Comparison of antioxidant activity, anthocyanins, carotenoids, and phenolics of three native fresh and sun-dried date (Phoenix dactylifera L.) varieties grown in Oman. J Agric Food Chem. 2005; 53:7592-9.
9. Breithofer A, Graumann K, Scicchitano MS, Karathanasis, SK, Butt TR, Jungbauer A. Regulation of human estrogen receptor by phytoestrogens in yeast and human cells. J Steroid Biochem Molec Biol. 1998; 67: 421-429.
10. Lotito SB, Frei B. Consumption of flavonoid-rich foods and increased plasma antioxidant capacity in humans: cause, consequence, or epiphenomenon? Free Radic Biol Med. 2006; 41:1727-46.
11. Guo H, An C, Gan Z, Mai E, Xing S, Chen R. Experimental study on antioxidant and calcium channel blockade preventing testicular fibrosis in rats. Zhonghua Nan Ke Xue. 2004; 10:857-63.
12. Aydilek N, Aksakal M, Karakilcik AZ. Effects of testosterone and vitamin E on the antioxidant system in rabbit testis. Andrologia 2004; 36:277-81.
13. Shiva M, Gautam AK, Verma Y, Shivgotra V, Doshi H, Kumar S. Association between sperm quality, oxidative stress, and seminal antioxidant activity. Clin Biochem. 2011; 44:319-24.
14. Aich S, Manna CK. Histopathological changes of testicular tissue due to busulfan administration in the wild Indian house rat (Rattus rattus). Acta Biol Hung 2001;52(1):105-16.
15. Nacz M, Shahidi F. Extraction and analysis of phenolics in food. Journal of Chromatography A, 2004 :95-111.
16. Lee OS, Kang HH, Han SH. Oriental herbs in cosmetics: Plant extracts are reviewed for their potential as cosmetic ingredients. Cosmet Toiletr 1997; 112:57-64.

17. Pritchett KR, Corning BF. Biology and Medicine of Rats, In: Laboratory Animal Medicine and Management, Reuter JD and Suckow MA (Eds.), International Veterinary Information Service, Ithaca NY. 2004.
18. Seed J, Chapin RE, Clegg ED, Dostal LA, Foote RH, Hurtt ME. Method for assessing sperm motility, morphology, and count in the rat, rabbit and dog: A consensus report. Reproductive Toxicology 1996; 10: 237-44.
19. Varghese AC, Das S, Bhattacharya AK, Bhattacharya SM, Mandal M, Agrawal A. Effect of cryoprotective additives-reduced glutathione, acetyl-L-carnitine on sperm membrane lipid peroxidation, DNA integrity and recovery of motile human sperm, Fert Steril 2005; 84: 410-411.
20. Terquem A, Dadoune JP. Aniline blue staining of human spermatozoon chromatin: Evaluation of nuclear maturation. Amsterdam: M Nijhoff, J Androl (ed), J Sperm Cell 1983: 249-252.
21. Muratori M, Piomboni P, Baldi E, Filimberti E, Pecchioli P, Moretti E. et al. Functional and ultrastructural features of DNA-fragmented human sperm. J Androl 2000; 21: 903-912.
22. Huynh T, Mollard R, Trounson A. Selected genetic factors associated with male infertility. Hum Reprod Update. 2002; 8:183-98.
23. Ali-Mohamed AY, Khamis AS. Mineral ion content of the seeds of six cultivars of Bahraini date palm (*Phoenix dactylifera*). J Agric Food Chem. 2004; 52:652.
24. Al-Shahib W, Marshall RJ. The fruit of the date palm: its possible use as the best food for the future? Int J Food Sci Nutr. 2003; 54:247-59.
25. Miyazawa M, Hisama M. Antimutagenic activity of Phenylpropanoids from clove (*Syzygium aromaticum*) J Agric Food chem. 2003; 51 (22):6413-6422
26. Miksicek RJ. Estrogenic flavonoids: structural requirements for biological activity. Proc. Soc. Exp Biol Med, 1995; 208 (1): 44-50.
27. Lucki NC, Sewer MB. Genistein stimulates mcf-7 breast cancer cell growth by inducing acid ceramidase (asah1) gene expression. J Biol Chem 2011 ; 286(22): 19399-19409. Doi/10.1074/jbc.M110.195826
28. Bennetau-Peisserro C, Berton BB, Bennetau B, Corraze G, Le Menn F, Davail-Cuisset B et al. Effects of genistin enriched diets on the endocrine process of gametogenesis and on reproduction efficiency of the rainbow trout *oncorhynchus mykiss*. Gen comp endocrinol. 2001;121:173-187.
29. Awoniyi CA, Roberts D, Veeramachaneni DN, Hurst BS, Tucker KE, Schlaff WD. Reproductive sequelae in female rats after in utero and neonatal exposure to the phytoestrogen genistein. Fertil. Steril, 70 ;1998: 440-447
30. Roberts D, Veeramachaneni DN, Schlaff WD, Awoniyi CA. Effects of chronic dietary exposure to genistein, a Phytoestrogen, During Various Stages of Development on Reproductive Hormones and Spermatogenesis in Rats. Endocrine 2000 ;13(3): 281-286
31. Nagao T, Yoshimura S, Saito Y, Nakagomi M, Usami K, Ono H. Reproductive effects of male and female rats of neonatal exposure to genistein. Reprod Toxicol. 2001; 15: 399 - 411.
32. Weber KS, Setchell KD, Stocco DM, Lephart ED. Dietary soy-phytoestrogen decrease testosterone levels and prostate weight without altering LH, prostate 5-alpha reductase or testicular steroidogenic acute regulatory peptide in adult male Sprague-Dawley rats. J Endocrinol. 2001; 170: 591 - 599.
33. Hess RA, Zhou Q, Nie R, Oliveira C, Cho H, Nakaia M, Carnes K. Estrogens and epididymal function. Reprod Fertil Dev 2001; 13: 273-83.
34. World Health Organization. Laboratory Manual for the Examination of Human Semen and Semen-Cervical Mucus Interaction, 4th edition. Cambridge, UK: Cambridge University Press. 2003 p. 60. ISBN 0-521-64599-9.
35. Choudhary R, Chawala VK, Soni ND, Jayant Kumar, Vyas RK. Oxidative stress and role of antioxidants in male infertility. Pak J Physiol 2010; 6(2):54-59.
36. Michael AJ, Alexopoulos C, Pontiki EA, Hadjipavlou-Litina DJ, Saratsis P, Ververidis HN. Effect of antioxidant supplementation in semen extenders on semen quality and reactive oxygen species of chilled canine spermatozoa. Animal Reproduction Science 2009; 112 (1-2):119-135.
37. Pietta P, Simonetti P, and Mauri P. Antioxidant Activity of Selected Medicinal Plants J. Agric. Food Chem., 1998, 46 (11): 4487-4490. DOI: 10.1021/jf980310p
38. Shahidi F, Janitha PK, & Wanasundara PD. Phenolic antioxidants. Critical Reviews of Food Science & Nutrition 1992, 32(1),67-103.
39. Aboua YG, Brooks N, Mahfouz RZ, Agarawal A and du Plessis SS. A red palm oil diet can reduce the effects of oxidative stress on rat spermatozoa. Andrologia 2012, 44: 32-40.
40. Chung SS, Wolgemuth DJ. Role of retinoid signaling in the regulation of spermatogenesis. Cytogenet Genome Res. 2004; 105:189-202.
41. Meistrich ML, Trostle-Weige PK, Van Beek ME. Separation of specific stages of spermatids from vitamin A-synchronized rat testes for assessment of nucleoprotein changes during spermiogenesis. Biol Reprod. 1994; 51:334-44.
42. Khan PK, Sinha SP. Ameliorating effects of vitamin C on murine sperm toxicity induced by three pesticides (endosulfan, phosphamidon and mancozeb). Mutagenesis. 1996; 11: 33-36.
43. Bastway Ahmed M, Abdel-Salam Hasona N, and Abdel-Hamid Selemain H. Protective Effects of Extract from Dates (*Phoenix Dactylifera* L.) and Ascorbic Acid on Thioacetamide-Induced Hepatotoxicity in Rats. Iranian Journal of Pharmaceutical Research 2008, 7 (3): 193-201.