

Case Report: Ossification of Caroticoclinoid Ligament in a Human Skull



Masoud Ghorbani¹ , Gholam Reza Dashti^{2*} 

1. Applied Biotechnology Research Center, Baqiyatallah University of Medical Sciences, Tehran, Iran.

2. Department of Anatomical Sciences and Molecular Biology, School of Medicine, Isfahan University of Medical Sciences, Isfahan, Iran.



Citation Ghorbani M, Dashti GhR. Ossification of Caroticoclinoid Ligament in a Human Skull. *Anatomical Sciences*. 2020; 17(2):89-92.



Article info:

Received: 24 Dec 2018

Accepted: 12 Apr 2020

Available Online: 01 Jul 2020

Keywords:

Caroticoclinoid ligament, Skull, Internal carotid, Bone ossification

ABSTRACT

Introduction: The Anterior clinoid process (ACP) and middle clinoid process (MCP) are sometimes connected by an osseous bridge formed by the ossification of caroticoclinoid ligament (CCL), converting the distal end of the carotid sulcus into an ostium called the caroticoclinoid foramen (CCF). The internal carotid artery (ICA) passes through this foramen, which is developed due to the ossification of either the caroticoclinoid ligament or a dural fold present between anterior and middle clinoid processes and occasionally connecting posterior clinoid process (PCP) of the sphenoid bone. The presence of a bony CCF may compress ICA, leading to clinical implications by increasing the risks of ischemic and neurological disorders during surgical access by neurosurgeons. It may also affect the hypothalamus or induce neurological problems by compressing optic or oculomotor nerves, causing hormonal imbalances, visual problems, headache, behavioral changes, etc. Regarding the clinical significance of CCF, this study aimed to evaluate the anatomical relationship and morphology of the CCF to plan a safe and successful surgery on the middle cranial fossa.

Methods: The presence of ossified CCL was noticed in a dry human skull. The morphometry was performed by a manual caliper, and the detailed measurements of the CCL, CCF, ACP, and MCP dimensions were performed and recorded.

Results: Considering these facts, detailed anatomical knowledge of this region is of clinical importance for neurosurgeons, neurophysicians, endocrinologists, and radiologists for radiological evaluations of the CCL and its treatment in the middle cranial fossa.

Conclusion: The growing awareness of differences in anatomical landmarks in the skull base can support the diagnosis and treatment of clinical complications related to the parasellar region.

* Corresponding Author:

Gholam Reza Dashti

Address: Department of Anatomical Sciences and Molecular Biology, School of Medicine, Isfahan University of Medical Sciences, Isfahan, Iran.

Tel: +98 (31) 37929040

E-mail: dashti@med.mui.ac.ir

1. Introduction

The medial end of the lesser wing of the sphenoid bone forms the Anterior Clinoid Process (ACP), which provides attachment to the free margin of the tentorium cerebelli and is grooved medially by the internal carotid artery [1-3]. ACP is connected to the Middle Clinoid Process (MCP) by the Caroticoclinoid Ligament (CCL), which is sometimes ossified. The presence of bony ligamentous structures is observed frequently in different regions of the human body causing clinical problems by pressing neighboring structures and leading to complications during regional surgery. Some parts of sphenoid bone are found to be attached by ligaments, which later on get ossified like pterygospinous ligament, interclinoid ligament (between ACP and PCP), and the CCL (between ACP and MCP) [4-7]. The Caroticoclinoid Foramen (CCF) is either due to ossification of CCL or dural fold present between ACP and MCP of sphenoid bone [8, 9]. The fibrous ossification of ligaments is considered a normal physiological process that occurs with aging; however, this process is an exception when one considers the formation of the CCF [8].

Keyes reported the prevalence of three types of anatomical variations of CCF in the human dry skull: the complete type, showing a bony ring or foramen; the contact type, presenting a line or suture connecting ACP and MCP; and incomplete type, where a bony extension is present between ACP and MCP medially which does not touch each other [10] (Figure 1). Because of its location in the skull, these characteristic features lead to clinical implications, which are of great significance to neuroanatomy and neurosurgeons.

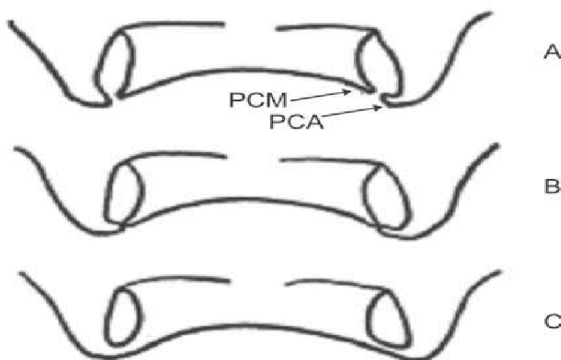


Figure 1. Types of caroticoclinoid foramen: Processus Clinoides Anterior (PCA), Processus Clinoides Medius (PCM), A-incomplete form, B-contact form, C-complete form (according to Keyes method)

The ICA is commonly reported to have six segments [2]. The portion of the artery traversing between the proximal and distal dural rings is known as the clinoid segment which is exposed during surgical removal of the ACP. It is critically important for neurosurgeons to know about the ossification of the CCL for safe surgical exposure of suprasellar and parasellar regions for many lesions like jugum sphenoidale, clinoidal, and tuberculum sellae meningiomas, paraclinoidal aneurysms, and cavernous sinus tumors in neurosurgical operations. However, the anatomical variations and relationships of the ACP, optic nerve, optic chiasma, ICA, and ophthalmic artery are very important and complex, as this region is affected by many neoplastic and neurovascular tissues. The removal of ACP is an important step in exposing the structures in the cavernous sinus and is highly complicated due to the neuronal and vascular relationships. The presence of the bony CCF makes the surgical removal of ACP more critical and complicated, especially during an aneurysm of ICA [11-13]. However, a paucity of studies exists about the ethnic variants of the morphology and anatomical relationships of bony landmarks for neurosurgeons. The sellar region has been an area of confusion among surgeons, because of variable morphology and anatomical relationship to vital structures. Despite several anatomical, clinical, and radiological studies, this case report tries to explore and increase the success of diagnostic evaluation with a more in-depth understanding of the skull-based surgical approach of this region by neurosurgeons.

This study aimed to focus on CCL variations and evaluate its occurrence in a dry skull, as well as to perform its morphometry.

2. Case report

The present study reported a bilateral completely ossified CCL in a dry skull of a woman obtained from the

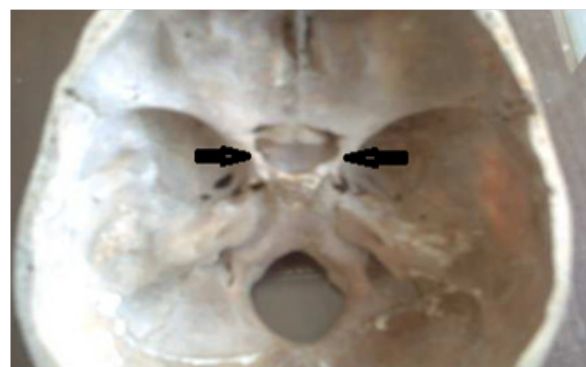

Figure 2. Ossified caroticoclinoid and interclinoid ligament (complete caroticoclinoid foramen)

Department of Anatomy and Molecular Biology, School of Medicine of Isfahan University of Medical Sciences, Isfahan City, Iran (Figure 2).

The incidence of a complete bony fibrous ligament in the dry human skull was observed between ACP and PCP. All appropriate morphometric measurements were performed by using a manual caliper and measuring the major diameter of each foramen. The measurements were performed 3 times to avoid errors by the same examiner by considering the repeated values. The measurements were obtained in millimeters. The transverse diameter of the foramen on both sides of the skull was 10 mm and the length of the bony bar distance between anterior and posterior clinoid processes was 14 mm in this case. The interclinoid distance between the two anterior clinoid processes was found to be 25 mm and between the two posterior clinoid processes was 18 mm. Caroticoclinoid foramen was also found bilaterally between the ACP and middle clinoid process (Figure 2).

3. Discussion

This study tried to define a safer anatomical plan for approaches in clinical implications and problems such as compression of neighboring structures and complications, which are of great significance for neurosurgeons in regional surgery. The ossification of CCL produces CCF that connects the anterior and middle clinoid processes and appears as age increases [2]. Others have reported that CCF ossification is not age-related [8]. Moreover, the formation of this foramen may cause compression and narrowing of the internal carotid artery, located medially to the ACP [4]. Changes in the internal carotid artery may cause compression of the cavernous sinus because of its medial position. Das et al. reported that the presence of the CCF causes morphological changes in the internal carotid artery in almost all cases. These variations occur due to the presence of foramen, which causes difficulty in performing a neurosurgical technique in the region [14].

ICA is commonly reported to have 6 segments, and the segment traversing between the proximal and distal end of dural rings is known as the clinoidal segment [2]. During surgical operation and the exposure of clinoidal segment of ICA, the excision of ACP is mandatory. When exposure of the cavernous sinus is carried out superiorly for managing paraclinoidal aneurysm, ACP is excised. The incidence of CCF causes serious complications resulting in a higher possibility of serious bleeding in this region [9, 10, 15]. Moreover, the prevalence of this foramen which is located medial to ACP causes pressure,

leading to narrowing of ICA [4]. This incidence may cause pressure on the cavernous sinus, which is situated medially. Das et al. observed in almost all cases that the CCF leads to morphological changes in ICA.

ICA was measured bilaterally indicating great caliber in this portion, showing signs of headache caused by compression and pressure of this foramen.

The choice of surgery is to remove ACP. The present study and Erturk et al. measured CCF diameter and demonstrated that this foramen could result in complications in ICA. In the present study, the transverse diameter of the foramen on both sides of the skull was 10 mm and the length of the bony bar distance was 14 mm in this case. This morphometric feature is crucial for fewer complications and can contribute to better surgical planning and outcome. In light of rapid progress in endoscopic surgery, the awareness of population differences in CCF morphometry is essential for safe surgical maneuvers while using novel procedures and approaches. To our knowledge, this is the first report of a morphological assessment of the CCF between anterior and posterior clinoid processes in Iranian adult dry skull. Therefore, the growing awareness of population differences in anatomical landmarks in the skull base can support the diagnosis and treatment of clinical complications related to the parasellar region.

Ethical Considerations

Compliance with ethical guidelines

There was no ethical consideration to be considered in this research.

Funding

This research did not receive any grant from funding agencies in the public, commercial, or non-profit sectors.

Authors' contributions

Conceptualization: Masoud Ghorbani; Methodology: Gholam Reza Dashti; Investigation: Both authors; Writing-review & editing: Gholam Reza Dashti;

Conflict of interest

The authors stated no conflicts of interest.

References

- [1] Standring S. Intracranial Region: Gray's Anatomy, The Anatomical Basis of Clinical Practice: 40th Ed, Spain: Churchill Livingstone, Elsevier; 2008.
- [2] Erturk M, Kayalioglu G, Govsa F. Anatomy of the clinoid region with special emphasis on the caroticoclinoid foramen and interclinoid osseous bridge in a recent Turkish population. *Neurosurgical Review*. 2004; 27(1):22-6. [DOI:10.1007/s10143-003-0265-x] [PMID]
- [3] Standring S. Overview of the development of the head and neck head: Skull and mandible. In: Standring S, editor. *Gray's anatomy: The anatomical basis of clinical practice*. New York: Elsevier; 2005.
- [4] Inoue T, Rhoton Jr AL, Theele D, Barry ME. Surgical approaches to the cavernous sinus: A microsurgical study. *Neurosurgery*. 1990; 26(6):903-32. [DOI:10.1227/00006123-199006000-00001] [PMID]
- [5] Williams PL, Warwick R, Dyson M, Bannister L. *Gray's anatomy*, 37th ed. Edinburgh: Churchill Livingstone; 1989.
- [6] Sicher H, Du Brul EL. *Oral Anatomy*. 6th ed., Saint Louis: The C.V. Mosby Company; 1975.
- [7] Williams PL, Warwick R, Dyson M, Bannister L. *Gray's Anatomy*. 37th ed., Edinburgh: Churchill Livingstone. 1989.
- [8] Özdoğmuş Ö, Saka E, Tulay C, Gürdal E, Üzünlü İ, Cavdar S. The anatomy of the carotico-clinoid foramen and its relation with the internal carotid artery. *Surgical and Radiologic Anatomy*. 2003; 25(3-4):241-6. [DOI:10.1007/s00276-003-0111-4] [PMID]
- [9] Muthukumar V, Nanjundaiah K, Shetty Sh. Study of carotico clinoid foramen in dry human skull. *International Journal of Anatomy and Research*. 2017; 5(4.2):4630-34. [DOI:10.16965/ijar.2017.425]
- [10] Keyes JE. Observations on four thousand optic foramina in human skulls of known origin. *Archives of Ophthalmology*. 1935; 13(4):538-68. [DOI:10.1001/archophth.1935.00840040026002]
- [11] Dutta AK. *Essentials of human anatomy part-II*. Calcutta: Current Books International; 1999.
- [12] Dolenc V. Direct microsurgical repair of intracavernous vascular lesions. *Journal of Neurosurgery*. 1983; 58(6):824-31. [DOI:10.3171/jns.1983.58.6.0824] [PMID]
- [13] Yonekawa Y, Ogata N, Imhof HG, Olivecrona M, Strommer K, Kwak TE, et al. Selective extradural anterior clinoidectomy for supra-and parasellar processes. *Journal of Neurosurgery*. 1997; 87(4):636-42. [DOI:10.3171/jns.1997.87.4.0636] [PMID]
- [14] Das S, Suri R, Kapur V. Ossification of caroticoclinoid ligament and its clinical importance in skull-based surgery. *Sao Paulo Medical Journal*. 2007; 125(6):351-3. [DOI:10.1590/S1516-31802007000600009] [PMID]
- [15] Ghorbani M, Dashti GR, Karimi Z, Mirhosseini MM, Golmohammadi R. The Existence of Caroticoclinoid Foramen in Skulls Available at the Department of Anatomy and Molecular Biology of Isfahan University of Medical Sciences, Iran. *Journal of Isfahan Medical School*. 2012; 30(208):1580-85. <https://web.b.ebscohost.com/abstract?>