

Research Paper: Measuring Dimensions of Lumbar Intervertebral Discs in Normal Subjects

Seyed Mohammad Hadi Mirab¹, Mohammad Barbarestani¹, Seyyed Mohammad Tabatabaei², Soodeh Shahsavari³, Mohammad Bagher Minaeii Zangi^{1*}

1. Department of Anatomy, School of Medicine, Tehran University of Medical Sciences, Tehran, Iran.

2. Department of Medical Informatics, Faculty of Paramedical Sciences, Shahid Beheshti University of Medical Sciences, Tehran, Iran.

3. Department of Health Information Management, Faculty of Paramedical Sciences, Kermanshah University of Medical Sciences, Kermanshah, Iran.

Citation: Mirab SMH, Barbarestani M, Tabatabaei SM, Shahsavari S, Minaeii Zangi MB. Measuring Dimensions of Lumbar Intervertebral Discs in Normal Subjects. *Anatomical Sciences*. 2018; 15(1):3-8.



Dr. Mohammad Bagher Minaeii Zangi started his university education at the Bachelor of Biology Department at Arak University. Then, He continued his education at the Department of Histology and Embryology at Tarbiat Modares University and finally received his degree in histology from the same university. He currently holds a Ph.D. degree as an associate professor in the Department of Anatomy at Tehran University of Medical Sciences.

Article info:

Received: 24 Aug 2016

Accepted: 08 Nov 2017

Available Online: 01 Jan 2018

ABSTRACT

Introduction: Disc degeneration is a natural aging process characterized by changes in appearance and chemical structure of the disc. This degeneration leads to back pain. In regard to the limitation of current therapeutical methods for patients with degenerated discs, arthroplasty has been suggested as an alternative method. To manufacture artificial discs for Iranians, determining normal lumbar intervertebral disc dimensions is necessary. Thus, we measure the most important dimensions of normal lumbar intervertebral discs in Iranians using Magnetic Resonance Imaging (MRI).

Methods: we studied lumbar intervertebral discs of 34 people who were 40-60 years old in Medical Imaging Center of Imam Khomeini Hospital. Out of them, 14 people without herniated disc and any other abnormalities related to spinal column on MRI were selected. There were 7 males and 7 females, and their average age was 48.07 years (range: 40 to 59 years). For accurate measurements, the relevant disc distances were measured by two radiologists and then the mean value for each segment was calculated.

Results: The mean (SD) values of anterior intervertebral disc height for L1/L2 to L5/S1 levels were measured and found as follows: 10.82(1.59) mm, 13.09(1.21) mm, 15.21(1.24) mm, 18.14(1.49) mm, 18.71(1.61) mm. The mean (SD) values of middle intervertebral disc height for L1/L2 to L5/S1 levels were measured as follows: 10(1.89) mm, 11.59(1.51) mm, 12.45(1.79) mm, 13.82(1.96) mm, 12.99(2.53) mm. The mean (SD) values of posterior intervertebral disc height for L1/L2 to L5/S1 levels were found as follows: 7.31(1.71) mm, 8.58(1.66) mm, 9.08(1.22) mm, 10.14(1.01) mm, 8.51(1.08) mm. The mean (SD) values of anterior-posterior disc length for L1/L2 to L5/S1 levels were found as follows: 30.23(2.71) mm, 32.03(2.43) mm, 32.86(2.44) mm, 33.08(2.37) mm, 31.33(2.55) mm. The mean (SD) values of transversal disc length for L1/L2 to L5/S1 levels were found as follows: 48.24(2.23) mm, 51.27(1.92) mm, 52.59(1.69) mm, 55.12(1.69) mm, 52.87(2.14) mm.

Conclusion: Knowledge of the normal lumbar intervertebral disc dimensions in every society is useful for surgical reconstruction to treat lumbar spine diseases and for medical manufacturers to make proper surgical devices in this regard.

Key Words:

Lumbar intervertebral disc,
Magnetic resonance imaging,
Degeneration, Measurement

* Corresponding Author:

Mohammad Bagher Minaeii Zangi, PhD

Address: Department of Anatomy, School of Medicine, Tehran University of Medical Sciences, Tehran, Iran.

Tel: +98 (912) 3573557

E-mail: seyed.mirab@gmail.com

1. Introduction

Back pain is a major public health problem in developed countries. It causes suffering and distress for patients and their families; the point prevalence in a number of studies ranged from 12% to 35% [1] also around 10% of sufferers became chronically disabled. It also places an enormous economic burden on society; its total cost, including direct medical costs, insurance, lost production and disability benefits is estimated to be £12 billion per annum in the UK and 1.7% of the gross national product in the Netherlands [1, 2]. Magnetic Resonance Imaging modality (MRI) is a useful technique for correct diagnosis of radiating pain to the lower extremities, herniated disc, lumbar spine stenosis and other spinal related disorders. MRI is non-invasive and provides diverse information about soft tissues of lumbar area thorough pictures of sagittal and axial planes [3-5]. In other words, soft tissue contrast resolution is better and there are no artifacts due to high-density skeletal structures [6].

Back pain is strongly associated with degeneration of the intervertebral disc [7, 8]. Actually, disc degeneration is a natural aging process characterized by changes in appearance and chemical structure of the disc which leads to back pain [9, 10]. Disc degeneration, although in many cases asymptomatic, is also associated with sciatica and disc herniation or prolapse. At the moment, there is no definite way to cure or postpone this degeneration process [11]. The suggested methods are divided into two main groups; surgical and non-surgical method. Non-surgical methods such as applying different external fixatives are used in a lumbar area with less damaged intervertebral discs. On the other hand, surgical-dependent methods use fusion, disc replacement, and mechanical fixatives to treat affected people. Of these methods, mechanical fixatives are applied in minimum damaged discs whereas fusion method and arthroplasty are useful for treating patients with a severely degenerated discs [12]. With regard to the

limitation of existing therapeutical methods for patients with the degenerated discs, arthroplasty is suggested as an alternative method [13].

Artificial disc replacement is an example of operative methods that have been recently introduced to restore the intervertebral disc space so that the segmental movement maintains [14-16]. Therefore, if the size of lumbar intervertebral discs for Iranians is known, Iranian engineers and specialists in the field of tissue engineering can collaborate with each other to manufacture Iranian type of artificial discs. Also, a standard list of Iranian normal lumbar intervertebral disc dimensions can be established to diagnose lumbar intervertebral disc degeneration by using the obtained measurements.

2. Materials and Methods

This study was conducted on 34 people who voluntary visited the Medical Imaging Center of Imam Khomeini Hospital Complex affiliated to Tehran University in 2016. All of them were informed of the study steps and ensured of the safety study procedure. Then, according to the MRI images (obtained by T1 and T2 sequences), only 14 people, who had normal lumbar intervertebral discs, were selected to enter the study. Of them, there were 7 males with average (SD) age of 48.43(5.44) year and 7 females with average (SD) age of 47.71(7.09) year. MRI scans were performed with high field 3 Tesla magnetic resonance system (Trio, Siemens, Erlangen, Germany) with Synergy Spine Coil in some cases and combined body/surface coil in the others.

To evaluate the lumbar intervertebral disc, the lumbar spine of participants was scanned in the supine position and the following sequences were performed on all patients, so that, slices were placed in the plane of the five lower discs: A localizer sequence of three images, 150/10/45 degrees (TR/TE/flip angle), including one sagittal, one coronal and one axial plane; Sagittal

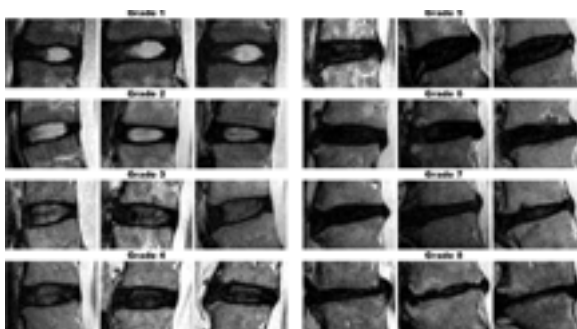


Figure 1. Modified Pfirrmann Grading System for Lumbar Intervertebral Disc Degeneration

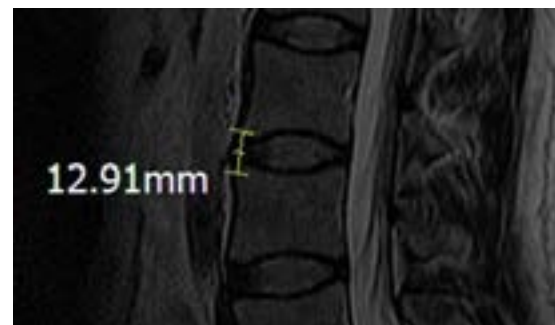


Figure 2. Anterior intervertebral height



Figure 3. Middle intervertebral height

T1-weighted spin-echo, 700/35 (TR/TE), 384×256 matrix, 340 mm FOV, 11 slices of 3 mm thickness, interslice gap of 0.5 mm, 1 acquisition, 1 min 50 s scan time; Sagittal T2-weighted turbo spin-echo, 3500/90 (TR/TE), 384×256 matrix, 340 mm FOV, 11 slices of 3 mm thickness, interslice gap of 0.5 mm, 1 acquisition, 1 min 50 s scan time; Axial T2-weighted fast spin-echo, 3500/85 (TR/TE), 320×256 matrix, 200 mm FOV, 16 slices of 4 mm thickness, interslice gap of 0.5 mm, 1 acquisition, 2 min scan time.

To distinguish normal lumbar intervertebral discs from abnormal ones, modified Pfirrmann grading system was used (Figure 1). In this study, the vertebral disc mid-sagittal section of vertebral discs was selected by the research team to measure the horizontal and vertical lengths but the axial section was chosen for measuring transverse dimension. The scale for each dimension is discussed below:

Anterior Intervertebral Height (AIVH)

The distance between the most anterior point at superior corner and most anterior point at the inferior corner of vertebrae located at the relevant intervertebral disc (Figure 2).

Middle Intervertebral Height (MIVH)

The distance between the point connecting the central part of the lower margin of the upper lumbar vertebra and the central part of the upper margin of the lower lumbar vertebra (Figure 3).

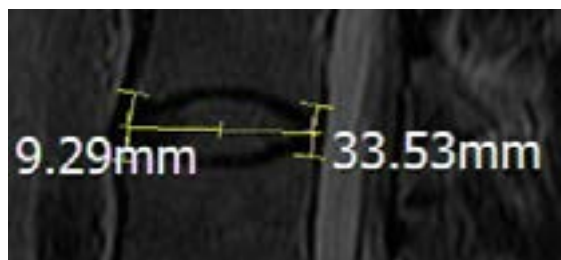


Figure 5. Anterior-posterior disc length

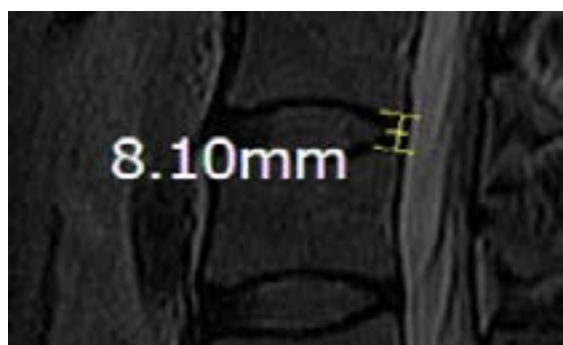

Figure 4. Posterior intervertebral height

Posterior Intervertebral Height (PIVH)

The distance between the most posterior point at superior corner and most posterior point at the inferior corner of vertebrae located at the relevant intervertebral disc (Figure 4).

Anterior-Posterior Disc Length (APDL)

The distance between the midway of AIVH and the midway of PIVH (Figure 5).

Transversal Disc Length (TDL)

The distance between the most lateral point of the lumbar intervertebral disc on one side to the most lateral point of the lumbar intervertebral disc on the other side (Figure 6).

3. Results

In the male group, the mean (SD) values for AIVH, MIVH, PIVH, APDL and TDL were respectively as 11.48(1.92) mm, 10.48(2.04) mm, 7.38(1.10) mm, 31.31(2.75) mm, and 49.76(2.26) mm at L1/L2 level; 13.77(2.04) mm, 12.51(1.54) mm, 8.62(1.29) mm, 32.83(2.62) mm, and 53.63(2.35) mm at L2/L3 level; 15.94(2.46) mm, 12.72(1.75) mm, 8.55(1.78) mm,

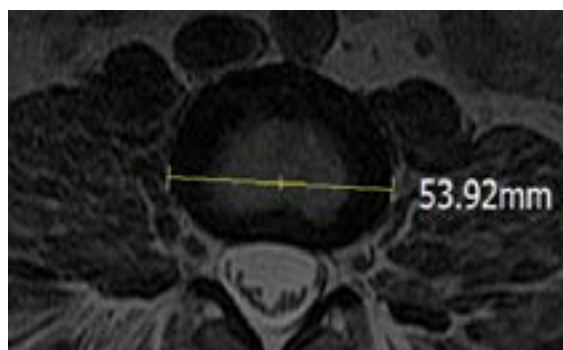


Figure 6. Transversal disc length

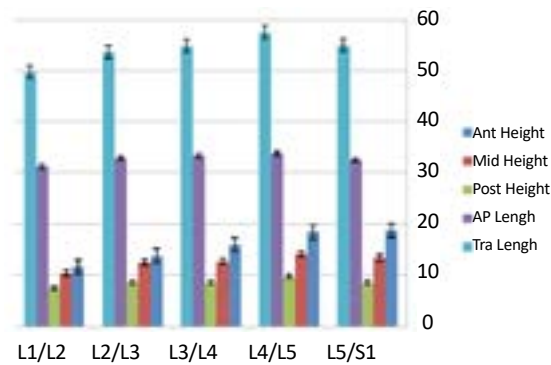


Figure 7. Dimensions mean value in men, with considering the standard error

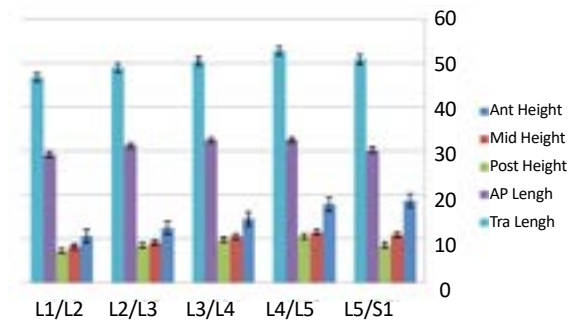


Figure 8. Dimensions mean value in women, with considering the standard error

Table 1. Mean values of all participants

	L1/L2	L2/L3	L3/L4	L4/L5	L5/S1
AIVH	10.82	13.09	15.21	18.14	18.71
MIVH	10	11.59	12.45	13.82	12.99
PIVH	7.31	8.58	9.08	10.14	8.51
APDL	30.23	32.03	32.86	33.08	31.33
TDL	48.24	51.27	52.59	55.12	52.87

unit: mm

33.38(2.19) mm, and 54.86(2.45) mm at L3/L4 level; 18.39(1.74) mm, 14.19(2.20) mm, 9.73(2.03) mm, 33.81(2.44) mm, and 57.54(3.63) mm at L4/L5 level; 18.78(2.82) mm, 13.36(3.88) mm, 8.51(2.60) mm, 32.54(2.94) mm, and 55(5.17) mm at L5/S1 level (Figure 7). In the female group, the mean (SD) values for AIVH, MIVH, PIVH, APDL and TDL were respectively as 11.48(1.72) mm, 10.48(1.48) mm, 7.38(0.92) mm, 31.31(2.58) mm, and 49.76(2.65) mm at L1/L2 level; 13.7(1.39) mm, 12.51(1.00) mm, 8.62(1.11) mm, 32.83(2.49) mm, and 53.63(3.39) mm at L2/L3 level; 15.94(1.15) mm, 12.72(1.08) mm, 8.55(1.79) mm, 33.38(2.41) mm, and 54.86(3.10) mm at L3/L4 level; 18.39(2.32) mm, 14.19(0.51) mm, 9.73(2.07)

mm, 33.81(2.51) mm, and 57.54(2.49) mm at L4/L5 level; 18.78(3.03) mm, 13.36(1.36), 8.51(1.42) mm, 32.54(3.22) mm, and 55(4.31) at L5/S1 level (Figure 8). Also, the overall mean (SD) values of these dimensions have been shown in Table 1 (Figure 9).

4. Discussion

To recover the height of normal intervertebral disc, some therapeutic procedures like spine fusion or artificial intervertebral disc replacement is performed. Regarding the spine fusion, the intervertebral segment fusion rate, and the intervertebral foramen height, the factors that are very important for patients related to the accomplished therapeutic procedure, are associated with the height of artificial structures inserted into the intervertebral disc space. Artificial intervertebral discs should move similar to normal disc movements to prevent the excess loading on the facet joint or distraction [17]. On the other hand, renewal of appropriate intervertebral disc space is an important factor because if the height of an intervertebral disc is too high, it may induce pain of facet joint and if it is low, it may induce early facet joint degeneration change [18].

Because the shape and size of artificial discs and instruments currently used are restricted, in this study, we measured some normal dimensions of Iranian lumbar

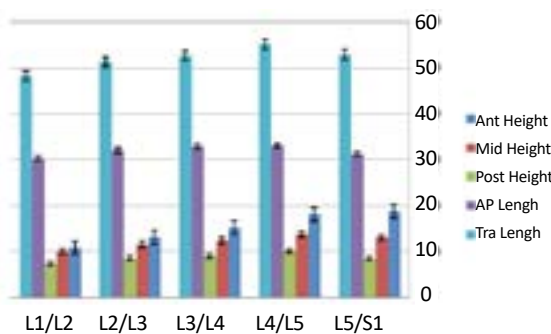


Figure 9. Dimensions mean value in men and women, with considering the standard error

intervertebral disc by performing MRI, which enable the medical engineers to manufacture instruments according to normal values of Iranian patients. The results indicated that the mean value of measured dimensions of lumbar intervertebral discs in the male populations showed an increase from L1/L2 level to L4/L5 level, whereas these dimensions decreased at L5/S1 level. On the other hand, in the group of healthy females, anterior-posterior disc length at L3/L4 level was approximately the same as this value at L4/L5 level. Anterior intervertebral height increased from L1/L2 to L5/S1 whereas rest of the values showed an increase from L1/L2 to L4/L5 levels and after that, the mentioned values decreased.

To perform an operation on these patients with minimal side-effects, using suitable surgical instruments are strongly recommended. Thus, through this study, approximate measurements of normal lumbar intervertebral discs can be found useful for the production of devices fitted to Iranian people. Chang Hwa Hong et al. (2010) studied anterior disc height, middle disc height, posterior disc height and horizontal length from vertebra L1 to vertebra S1 (including five lumbar intervertebral spaces) on 178 outpatients who had low back pain and undergone lumbar MRI. The results of Chang study demonstrate that mean values which were measured for Korean people are less than mean values measured in the current study. The mean values related to all patients' lumbar intervertebral discs in Chang study were measured and found as 7.12, 8.41, 9.73, 10.92, and 9.74 mm for anterior disc height, 8.48, 9.12, 9.80, 10.83 and 9.77 mm for middle disc height, 5.78, 6.20, 7.24, 7.32 and 6.20 mm for posterior disc height and 28.43, 30.15, 31.13, 32.83 and 33.10 mm for horizontal length of disc.

Acknowledgments

This paper was extracted from a MSc. thesis and was financially supported by Tehran University of Medical Sciences. The authors thank Dr. M. Jalilvand, Dr. R. Pourghorban, Dr. S. Khosravi, and all of them who assisted us in Medical Imaging Center of Imam Khomeini Hospital Complex, Tehran.

Conflict of Interest

The authors declared no conflicts of interest.

References

- [1] Maniadakis N, Gray A. The economic burden of back pain in the UK. *Pain*. 2000; 84(1):95-103. doi: 10.1016/s0304-3959(99)00187-6
- [2] Van Tulder MW, Koes BW, Bouter LM. A cost-of-illness study of back pain in The Netherlands. *Pain*. 1995; 62(2):233-40. doi: 10.1016/0304-3959(94)00272-g
- [3] Tunset A, Kjaer P, Samir Chreiteh S, Secher Jensen T. A method for quantitative measurement of lumbar intervertebral disc structures: an intra- and inter-rater agreement and reliability study. *Chiropractic & Manual Therapies*. 2013; 21(1):26. doi: 10.1186/2045-709x-21-26
- [4] Houghton V. The "dehydrated" lumbar intervertebral disk on MR, its anatomy, biochemistry and biomechanics. *Neuroradiology*. 2011; 53(S1):191-4. doi: 10.1007/s00234-011-0923-6
- [5] Niemeläinen R, Videman T, Dhillon SS, Battié MC. Quantitative measurement of intervertebral disc signal using MRI. *Clinical Radiology*. 2008; 63(3):252-5. doi: 10.1016/j.crad.2007.08.012
- [6] Cassar-Pullicino VN. MRI of the ageing and herniating intervertebral disc. *European Journal of Radiology*. 1998; 27(3):214-28. doi: 10.1016/s0720-048x(97)00169-1
- [7] Luoma K, Riihimäki H, Luukkonen R, Raininko R, Viikari-Juntura E, Lamminen A. Low pain in relation to lumbar disc degeneration. *Spine*. 2000; 25(4):487-92. doi: 10.1097/00007632-200002150-00016
- [8] Cassinelli EH, Kang JD. Current understanding of lumbar disc degeneration. *Operative Techniques in Orthopaedics*. 2000; 10(4):254-62. doi: 10.1016/s1048-6666(00)80025-7
- [9] Smith LJ, Nerurkar NL, Choi KS, Harfe BD, Elliott DM. Degeneration and regeneration of the intervertebral disc: lessons from development. *Disease Models & Mechanisms*. 2010; 4(1):31-41. doi: 10.1242/dmm.006403
- [10] Boos N, Weissbach S, Rohrbach H, Weiler C, Spratt KF, Nerlich AG. Classification of age-related changes in lumbar intervertebral discs. *Spine*. 2002; 27(23):2631-44. doi: 10.1097/00007632-200212010-00002
- [11] Miwa S, Yokogawa A, Kobayashi T, Nishimura T, Igarashi K, Inatani H, et al. Risk Factors of Recurrent Lumbar Disk Herniation. *Journal of Spinal Disorders & Techniques*. 2015; 28(5):E265-E269. doi: 10.1097/bsd.0b013e31828215b3
- [12] Shih KS, Hsu CC, Zhou SY, Hou SM. Biomechanical investigation of pedicle screw-based posterior stabilization systems for the treatment of lumbar degenerative disc disease using finite element analyses. *Biomedical Engineering: Applications, Basis and Communications*. 2015; 27(6):1550060. doi: 10.4015/s101623721550060x
- [13] Sengupta DK. *Clinical Biomechanics of the Spine*. Spine. 2017; 42:S3. doi: 10.1097/brs.0000000000002019
- [14] Goel VK, Grauer JN, Patel TC, Biyani A, Sairyo K, Vishnubhotla S, et al. Effects of Charite artificial disc on the implanted and adjacent spinal segments mechanics using a hybrid testing protocol. *Spine*. 2005; 30(24):2755-64. doi: 10.1097/01.brs.0000195897.17277.67

- [15] Grauer JN, Biyani A, Faizan A, Kiapour A, Sairyo K, Ivanov A, et al. Biomechanics of two-level Charite artificial disc placement in comparison to fusion plus single-level disc placement combination. *The Spine Journal*. 2006;6(6):659-66. doi: 10.1016/j.spinee.2006.03.011
- [16] Hollister SJ, Liao EE, Moffitt EN, Jeong CG, Kemppainen JM. Defining design targets for tissue engineering scaffolds. *Fundamentals of Tissue Engineering and Regenerative Medicine*. Berlin: Springer; 2009.
- [17] Tournier C, Aunoble S, Le Huec J, Lemaire J, Tropiano P, Lafage V, et al. Total disc arthroplasty: consequences for sagittal balance and lumbar spine movement. *European Spine Journal*. 2007; 16(3):411-21. doi: 10.1007/s00586-006-0208-7
- [18] Hong CH, Park JS, Jung KJ, Kim WJ. Measurement of the normal lumbar intervertebral disc space using magnetic resonance imaging. *Asian Spine Journal*. 2010; 4(1):1-6. doi: 10.4184/asj.2010.4.1.1