

Case Report: Ectopic Location of Permanent Tooth Germ Accompanied by Infraocclusion of Primary Second Molar

Masoumeh Aminizadeh¹, Fatemeh Jahanimoghadam^{2*}

1. Department of Pediatric Dentistry, School of Dentistry, Kerman University of Medical Sciences, Kerman, Iran.

2. Department of Pediatric Dentistry, School of Dentistry, Oral & Dental Research Center, Kerman University of Medical Sciences, Kerman, Iran.

Citation: Aminizadeh M, Jahanimoghadam F. Case report: Ectopic location of permanent tooth germ accompanied by infraocclusion of primary second molar. *Anatomical Sciences*. 2016; 13(1):67-69.



Dr. Fatemeh Jahanimoghadam is the assistant professor of Pediatric dentistry. She teaches Pediatric dentistry at Dental School, Kerman University of Medical Sciences, Iran. Her research interests are preventive dentistry and microbiology.

Article info:

Received: 15 Jan. 2015

Accepted: 07 Sep. 2015

Available Online: 01 Jan 2016

Key Words:

Ectopic, Infraocclusion, Malocclusion

ABSTRACT

We report the delayed eruption and infraocclusion of a mandibular second primary molar with ectopic location of the permanent successor. This was a rare case where the second premolar was located to the distal side of the impacted mandibular second primary molar. Early intervention is recommended to manage orofacial disfigurement and prevent consequent problems.

1. Introduction

Tooth eruption is described as the movement of a tooth from its normal position within the alveolar process towards its functional position in the oral cavity [1].

This process is accompanied by multiple tissue changes such as resorption and apposition of the alveolar bone as well as development of the root and periodontium [1, 2]. In some instances, anomalies in these physiological phenomena can cause impacted teeth. The impaction

may be primary, i.e. the tooth never erupts, or it may be secondary, i.e. the tooth is reimpaired after eruption [2]. Ankylosis is defined as any tooth that fails to erupt into a normal functional position and remains unerupted in the jaw beyond the time of its normal eruption [3]. It is a condition in which the cementum of a tooth's root fuses directly to the surrounding bone. The periodontal ligament is replaced with osseous tissue [2]. Among all primary teeth, the mandibular second primary molar has the highest incidence of semi-eruption or ankylosis [10].

* Corresponding Author:

Fatemeh Jahanimoghadam, PhD

Address: Department of Pediatric Dentistry, School of Dentistry, Oral & Dental Research Center, Kerman University of Medical Sciences, Kerman, Iran.

Tel: +98 (34) 32119021

E-mail: fatemehjahani4@gmail.com

Because impaction of a primary tooth with ectopic position of the succedaneous permanent tooth might disturb the growth of the permanent dental arch, detection and treatment of impacted primary teeth are essential [5].

Intraosseous migration of unerupted tooth is a rare and unusual dental anomaly, which occurs mostly in the permanent dentition of the lower jaw [6].

Infraocclusion of deciduous molars is often associated with ankylosis. Such teeth are believed to be potential sites of malocclusion, with a risk of tipping of adjacent teeth and loss of space.

Numerous local and systemic factors have been implicated in preventing single or multiple primary teeth from erupting within a normal range of time. Local factors generally cause only one or a few teeth to be delayed while systemic causes or genetic factors may affect many teeth or the entire dentition. Eruption delays in primary teeth can be usually attributed to fewer local causes compared to those, which can affect the permanent teeth [9]. This paper presents an unusual ectopic location of permanent tooth germ accompanied by infraocclusion of mandibular second primary molar.

2. Case Report

A 5-year-old boy was referred to the Department of Pediatric Dentistry, Faculty of Dentistry, University of Medical Sciences, Kerman, Iran. He was complaining of an abscess and pain in left mandibular second primary molar. The patient's medical and family history was non-contributory for pertinent findings. There was no history of orofacial trauma or unusual delay in primary incisor development. Oral examination showed a complete primary dentition in occlusion except for the mandibular left second primary molar (second primary molar was

in infraocclusion) (Figure 1). On intraoral examination, the occlusion was in distal step relationship. There was 2 mm of overjet and 2 mm of overbite. The maxillary and mandibular arch were symmetrical with spacing in the anterior region (Figure 2).

The oral hygiene was fair with mild gingivitis. Dental caries was another clinical finding but there were no other abnormal oral findings. Panoramic radiograph showed normal dental development in all quadrants except on the mandibular left side. Also, the mandibular left second primary molar was completely submerged with ectopic location of the permanent successor (Figure 3). A distal shoe was placed in the lower arch as a space maintainer. The patient was advised to return periodically at 6-month intervals for radiographic follow-up and evaluation of the second premolar retention. Any notable findings and subsequent orthodontic treatment would be considered in the future.

3. Discussion

In the present case, the most characteristic finding was the location of the second premolar in the distal side of the impacted mandibular second primary molar. There have been relatively few reports of impaction and tooth eruption failure in primary teeth compared to permanent teeth [3]. Impaction and eruption failure of primary teeth might be associated with a disturbance in permanent successors [5].

The etiology of tooth impaction includes systemic and local factors such as dental germ abnormality, eruption cyst, odontoma, tooth displacement, ankylosis, gingival hyperplasia, and eruption space deficiency [3]. The general treatment recommendation is to await normal exfoliation of infraoccluded primary molars. Continuous supervision of occlusal development and periodic radiographic control of normal root resorption are recommended, too. In special cases of occlusal disturbances

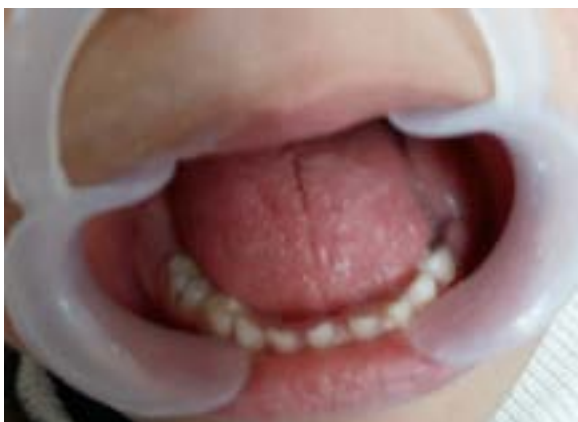

Figure 1. Intraoral view of the patient.

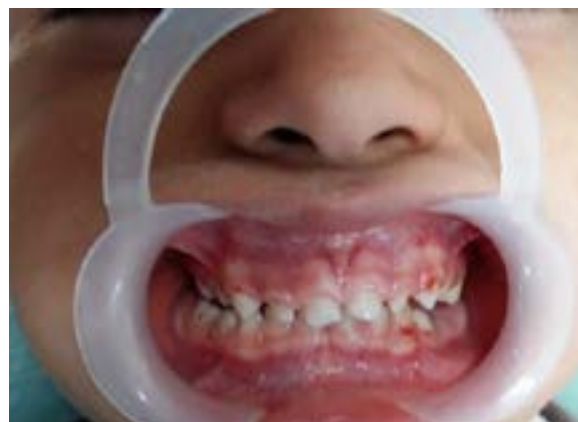

Figure 2. Occlusal view of the patient.

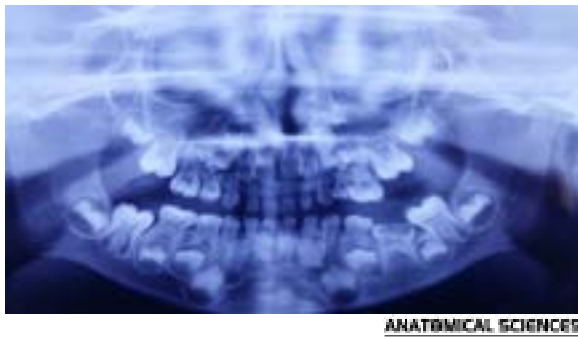


Figure 3. Mandibular left second primary molar in infraocclusion and ectopic location of permanent successor germ.

with severe tipping of adjacent teeth and space loss, the tooth must be extracted. Additionally, in malposition of the permanent successor preventing normal root resorption, extraction is necessary [7]. The same is recommended in severe infraocclusion.

During development, the dental germ of the lower second premolar originates from the successional tooth band at the lingual side of the dental germ of the mandibular second primary molar [8].

Early diagnosis as well as proper treatment and careful follow up are necessary in cases of severe infraocclusion of the primary molars when their marginal ridges are at or below gingival level. Pedodontists are highly recommended to detect the primary molar ankylosis to prevent distorted eruption of permanent dentition and avoid treatment complications. Furthermore, long-term observation is necessary until the permanent successors erupt.

Acknowledgements

The authors wish to thank the patient for his assistance in all periods of study. The current research hasn't received any financial support.

Conflict of Interests

The authors of this paper declared no conflict of interest in this paper.

References

- [1] Lautenschläger GA, Gallina MC, Ferreira Júnior O, Lara VS. Primary failure of tooth eruption associated with secondarily inflamed dental follicle: Inflammatory follicular cyst?. *Brazilian Dental Journal*. 2007; 18(2):144-47.
- [2] Rasmussen P, Kotsaki A. Inherited primary failure of eruption in the primary dentition: report of five cases. *ASDC Journal of Dentistry for Children*. 1997; 64(1):43-47.
- [3] Shalish M, Will LA, Shusterman S. Malposition of unerupted mandibular second premolar in children with cleft lip and palate. *Angle Orthodontist*. 2007; 77:1062-066.
- [4] McKibben DR, Brearley LJ. Radiographic determination of the prevalence of selected dental anomalies in children. *Journal of Dentistry for Children* 1971; 28(6):390-98.
- [5] Matsuyama J, Kinoshita-Kawano S, Hayashi-Sakai S, Mitomi T, Sano-Asahito T. Severe impaction of the primary mandibular second molar accompanied by displacement of the permanent second premolar. *Case Reports in Dentistry*. 2015; 2015:582462. doi: 10.1155/2015/582462
- [6] Kumar S, Urala AS, Kamath AT, Jayaswal P, Valiathan A. Unusual intraosseous transmigration of impacted tooth. *Imaging Science in Dentistry*. 2012; 42(1):47-54.
- [7] Shalish M, Chaushu S, Wasserstein A. Malposition of unerupted mandibular second premolar in children with palatally displaced canines. *Angle Orthodontist*. 2009; 79(4):796-99.
- [8] Järvinen SH. Unerupted second primary molars: Report of two cases. *ASDC Journal of Dentistry of Children*. 1994; 61(5-6):397-400.
- [9] Antoniadis K, Kavadia S, Milioti K, Antoniadis V, Markovitsi E. Submerged teeth. *Journal of Clinical Pediatric Dentistry*. 2002; 26(3):239-42.
- [10] Walker LM, Wood AJ, McDonald A, Carpenter W. Unerupted mandibular second primary molar with an unusual histopathological finding: A case report. *Journal of Dentistry for Children*. 2004; 71(1):77-79.