

A Case Report: Rare Communication of Ansa Cervicalis

Mohsen Nooroziyan ¹, Mohammad Bayat ¹, Reza Mastery Farahani ¹, Mohammad-Amin Abdollahifar ¹, Hadi Azimi ², Ali Noori-Zadeh ³, Azam Asemi Rad ¹, Somayeh Fallah Nejjad ¹, Maryam Salimi ¹, Rabieh Mohammadi ¹, Abdullah Amini ¹, Hojjat-Allah Abbaszadeh ^{1*}

1. Department of Biology and Anatomical Sciences, School of Medicine, Shahid Beheshti University of Medical Sciences, Tehran, Iran.

2. Department of English Language Teaching, School of Medicine, Shahid Beheshti University of Medical Sciences, Tehran, Iran.

3. Department of Medical Sciences, Shahrood Branch, Islamic Azad University, Shahrood, Iran.



Dr. Hojjat-Allah Abbaszadeh is an assistant professor at the School of Biology and Anatomy Sciences, Shahid Beheshti University of Medical Sciences and Health Services, Tehran, Iran. He teaches anatomy and embryology, and his research fields include neural stem cells, spinal cord injury, cell therapy, and gene therapy.

Article info:

Received: 03 Mar. 2015

Accepted: 22 Jun. 2015

Key Words:

Cervical plexus, Variation,
Vagus nerve, Nerve loop

ABSTRACT

During the past few years, researchers and practitioners have developed novel techniques, using ansa cervicalis to innervate muscles of the larynx paralyzed due to surgical procedures carried out in the chest and neck areas. During routine dissection of a middle-age male cadaver, an unusual course of the superior root of the ansa cervicalis was observed. In this case, the superior root of the ansa cervicalis fused with the vagus and ran within the carotid sheath, and then joined the inferior root forming the ansa cervicalis in the anterior wall of the carotid sheath. The study of this case will add to our current knowledge of ansa cervicalis and thus aid prevention of injury to the nerve during various surgical procedures.

1. Introduction

Ansa cervicalis is a nerve loop which is normally seen in the carotid triangle. It is formed by the union of superior and inferior roots. The superior root (descendens hypoglossi) contains fibers from the first cervical spinal nerve. After curving around the occipital artery, it leaves the hypoglossal nerve and runs down on the carotid sheath. Then, it provides a branch to the superior belly of omohyoid and

then joins the inferior root containing fibers from the second and third cervical spinal nerves to form a loop, known as ansa cervicalis. Its branches pass from the convexity of this loop to supply the sternohyoid, the sternothyroid, and the inferior belly of the omohyoid.

Recently, researchers have used ansa cervicalis to innervate muscles of the larynx paralyzed due to surgical procedures carried out in the chest and neck areas (e.g., surgeries of esophagus, thyroid). Among major complications in esophageal and thyroid cancer surgery is the

* Corresponding Author:

Hojjat-Allah Abbaszadeh, PhD

Address: Department of Biology and Anatomical Sciences, School of Medicine, Shahid Beheshti University of Medical Sciences, Tehran, Iran.

Tel: +98 (21) 223872555

Fax: +98 (21) 22439976

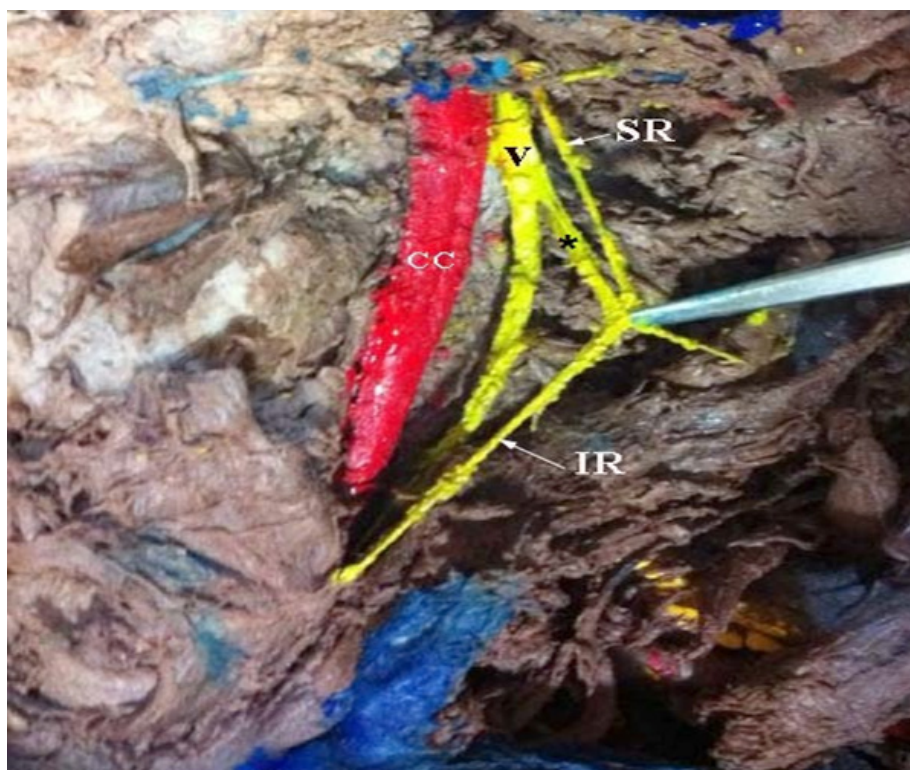
E-mail: hoomanabs@gmail.com

recurrent laryngeal nerve paralysis. Recently, surgeons prefer nerve muscle transplantation to paraglottic space after resection of the recurrent laryngeal nerve with ansa cervicalis [1]. One reason to use ansa cervicalis in this procedure is its proximity to the larynx. An increase in our knowledge of topographical relationships in this area, which necessarily includes its possible variations, leads to higher chance for a successful surgery [2].

The literature witnesses several variation reports such as variations in the origin, course, and branching of ansa cervicalis. A recent investigation reported a case of bilateral absence of ansa cervicalis; the infrahyoid muscles were instead supplied by a vagocervical plexus [3]. In another case, no loop of nerves was formed and the infrahyoid muscles were directly innervated by the superior root [4]. Also, several studies have reported the superior root arising from vagus in the observed cadavers [5-7]. According to the reports, ansa cervicalis is formed posterior to the carotid sheath [2], and others made use of extra cranial fusion of hypoglossal and vagus nerves [8-9]. The present report discusses the observation of the ansa cervicalis having an unusual course of the superior root.

2. Case Report

Observation of an unusual course of the superior root of ansa cervicalis on the right side of a middle-age male cadaver was made during the routine dissection for anatomy students in the Department of Anatomy, Shahid Beheshti University of Medical Sciences, Tehran, Iran. Normal course was observed for the hypoglossal nerve. When the hypoglossal turned round the occipital artery, it gave origin to 2 branches: one small branch ran in the anterior wall of the carotid sheath and supplied the superior belly of the omohyoid muscle and the other formed the superior root of ansa cervicalis (descendens hypoglossi). This superior root immediately joined the vagus and fused with it rather than running in the anterior wall of carotid sheath. The superior root then penetrated the carotid sheath and joined the inferior root to form ansa cervicalis in the anterior wall of the carotid sheath (Figure 1). From the loop of ansa cervicalis, two branches emitted: one supplied the superior belly of the omohyoid, sternothyroid, and sternohyoid muscles; and the other supplied the inferior belly of the omohyoid. Thus, 2 different branches supplied the superior belly of the omohyoid. Also, thyrohyoid muscle was supplied by



ANATOMICAL SCIENCES

Figure 1. Ansa cervicalis on the left side.

Abbreviations: CC, common carotid artery; IR, inferior root of ansa cervicalis; SR, superior root of ansa cervicalis; V, vagus nerve.

*: Communication between ansa cervicalis and vague nerve.

a branch from hypoglossal nerve. The formation and distribution of ansa cervicalis was normal on the left side.

3. Discussion

So far, several variations in the origin and course of ansa cervicalis have been reported. It is possible for the ansa to arise from the first, second, and third, or only from the second and third cervical nerves. It is also possible for descendens hypoglossi to be replaced by vagus. When ansa is absent, branches arising directly from C2 and C3 to innervate the infrahyoid muscles. The nerve to the thyrohyoid may arise as a branch of descendens hypoglossi. The descendens hypoglossi can also supply the phrenic nerve. The Literature also includes reports on variable connections of ansa cervicalis with cervical sympathetic trunk. The superior root of ansa cervicalis normally runs down on the carotid sheath and then joins the inferior root. As for the case in the current study, the fibers of the first cervical spinal nerve joined the hypoglossal, normally. Likewise, the hypoglossal nerve gave off the superior root of ansa as expected; yet, the superior root united the vagus and ran within the carotid sheath prior to forming the loop, instead of running in the anterior wall of the carotid sheath. In a similar study, a case was reported in which the superior root originated from the vagus; however, there was no mention of whether the fibers from the first cervical spinal nerve joined the hypoglossal and then accompanied the vagus, or they joined the vagus nerve directly [6]. Moreover, studies show that the superior root of ansa arises from the vagus while performing carotid endarterectomy. Nevertheless they did not state where and how the fibers of C1 joined the vagus [10].

According to a recent research, there are 2 broad communication categories between the ansa cervicalis complex and the vagus nerve: 1) false (pseudo) communications, where the 2 nerves are attached merely via the connective tissue with no fiber exchange and 2) true communications, which includes nerve fiber involvement [11]. It was only revealed after fiber analysis that the majority of the ansa vagal communications, observed during gross dissection, were of the first category. As for true communications, when present, they accounted for a small number of contributions and were always directed towards the side of the vagus. Additionally, we observed that the vagus (region of the inferior ganglion) and hypoglossal nerves were in close contact at the base of the skull and they could not typically be separated via gross dissection. The point is that such attachments, too, were shown to be virtually totally atypical except for the possible presence of a few fine nerve filaments.

Seemingly, the ansa vagal communications are merely close physical relationship between the 2 structures and do not serve a significant functional purpose. But then, the same ansa vagal communications finds significance to a surgeon, mainly because these communications can hinder the possibility of implementing ansa cervicalis in surgical procedures, including reinnervation of laryngeal and facial muscles.

Resorting to ansa cervicalis for laryngeal reinnervation required for vocal cord paralysis caused by recurrent laryngeal nerve damage has shown to be a successful procedure [12, 13]. The superior root and the branch to the sternothyroid muscle are commonly used for this purpose because of their close proximity to the recurrent laryngeal nerve. In addition, ansa cervicalis can be used after facial nerve palsy by reanimating the face, as well. In this procedure, surgeons prefer to use ansa cervicalis instead of hypoglossal nerve since it does not have late complications like defective speech and swallowing because of the scarred degeneration of the target muscles of the hypoglossal nerve.

Reports exist that a combination of facial hypoglossal anastomosis together with simultaneous myoplasty and anastomosis of the distal hypoglossal stump to the ansa cervicalis could minimize defects of this type [14]. That once more emphasizes the significance of ansa cervicalis in this type of treatment procedure.

From the embryological perspective, the myotome part of a somite divides into a dorsal portion, or epimere, and a ventral portion, or hypomere. These portions are innervated via the dorsal and ventral rami of the spinal nerves, respectively. The developing transverse processes of the vertebrae help separate the epimere and hypomere. The hypomeres are further divided into dorsomedial, lateral, and ventral portions. The ventral portions of the hypomeres of the cervical myotomes give origin to the strap muscles of the neck, that include the scalene and infrahyoid muscles, which are innervated by the ventral rami of the cervical spinal nerves. The fourth and sixth pharyngeal arches are innervated by the superior laryngeal and recurrent laryngeal branches of the vagus nerve. The occipital myotomes extend ventrally, shift cranially, and form the intrinsic and extrinsic musculature of the tongue. These are in turn innervated by the hypoglossal nerve. The embryological basis for this variation may be explained by the proximity between the cervical and the occipital myotomes [15].

In conclusion, the case examined in the current report displayed a variable course of the superior root of ansa

cervicalis, which after emitting from the hypoglossal nerve, joined the vagus prior to forming the loop. Surgeons' awareness of these ansa vagal communications enhances their knowledge of ansa cervicalis and prevents them from bringing about injury to the nerve during various surgical procedures.

Acknowledgements

The present study was sponsored by Shahid Beheshti University of Medical Sciences, Tehran, Iran. Our thanks go to Vahid Ebrahimi, Ali Rashidani, Elnaz Rahbar, Atosa Zirak Razieh Rohani for their contributions and assistance in the dissection.

References

- [1] Loukas M, Thorsell A, Tubbs R, Kapos T, Louis Jr R, Vulis M, et al. The ansa cervicalis revisited. *Folia Morphologica*. 2007; 66(2):120-5.
- [2] Machalek L, Charamza J, Kikalova K, Bezdekova M. A variant case of ansa cervicalis. *International Journal of Anatomical Variations*. 2009; 2:150-2.
- [3] Abu-Hijleh MF. Bilateral absence of ansa cervicalis replaced by vagocervical plexus: case report and literature review. *Annals of Anatomy-Anatomischer Anzeiger*. 2005; 187(2):121-5.
- [4] Venugopal SP, Mallula SB. Ansa cervicalis without loop. *International Journal of Anatomical Variations*. 2010; 3:153-55.
- [5] Manjunath K. Vagal origin of the ANSA cervicalis nerve-report of two cases. *Indian Journal of Otolaryngology and Head and Neck Surgery*. 2000; 52(3):257-8.
- [6] Vollala VR, Bhat S, Nayak SB, Raghunathan D, Samuel VP, Rodrigues V, et al. A rare origin of upper root of ansa cervicalis from vagus nerve: A case report. *Neuroanatomy*. 2005; 4:8-9.
- [7] Ayyoubian M, Koruji M. A rare anatomical variant of ansa cervicalis: case report. *Medical Journal of The Islamic Republic of Iran*. 2011; 24(4):238-40.
- [8] Verma R, Das S, Suri R. Unusual organization of the ansa cervicalis: A case report. *Brazilian Journal of Morphological Sciences*. 2005; 22(3):175-7.
- [9] Patel J, Shah R, Shah K, Nirvan A, Merchant S. Superior root of ansa cervicalis arising from vagus nerve. *Gujarat Medical Journal*. 2010; 65(1):11-3.
- [10] Accord RE, Reyntjens P, Samyn M, Reuwer J. Unusual origin of the ansa cervicalis observed during carotid endarterectomy. *Annals of Vascular Surgery*. 2010; 24(5):692.
- [11] Banneheka S, Tokita K, Kumaki K. Nerve fiber analysis of ansa cervicalis-vagus communications. *Anatomical Science International*. 2008; 83(3):145-51.
- [12] Crumley RL, Izdebski K. Voice quality following laryngeal reinnervation by ansa hypoglossi transfer. *Laryngoscope*. 1986; 96(6):611-6.
- [13] Miyauchi A, Matsusaka K, Kihara M, Matsuzuka F, Hirai K, Yokozawa T, et al. The role of ansa-to-recurrent-laryngeal nerve anastomosis in operations for thyroid cancer. *The European Journal of Surgery*. 1998; 164(12):927-33.
- [14] Kukwa A, Marchel A, Pietniczka M, Rakowicz M, Krajewski R. Reanimation of the face after facial nerve palsy resulting from resection of a cerebellopontine angle tumour. *British Journal of Neurosurgery*. 1994; 8(3):327-32.
- [15] Hamilton WJ, Mossman HW, Boyd JD. Hamilton, Boyd and Mossman's Human Embryology: Prenatal Development of Form and Function. London: Williams & Wilkins; 1972.