

Effect of Olive Leaf Extract in Inhibition of Renal Ischemia-Reperfusion Injuries in Rat

Houshang Rafighdoost¹, Majid Tavafi², Leila Jafari pour^{1*}, Bahram Rasoulia³, Hassan Ahmadvand⁴, Mona Mahmodi⁵, Marzyeh Rashidi Pour⁶

1. Department of Anatomy, School of Medicine, Zahedan University of Medical Sciences, Zahedan, Iran.
2. Department of Anatomy, Faculty of Medicine, Lorestan University of Medical Sciences, Khorramabad, Iran.
3. Razi Herbal Medicines Research Center, Lorestan University of Medical Sciences, Khorramabad, Iran.
4. Department of Biochemistry, Faculty of Medicine, Lorestan University of Medical Sciences, Khorramabad, Iran.
5. Department of Biochemistry, Payam Noor University, Taft Branch, Yazd, Iran.
6. Khorram Abad Branch, Young Researchers Club, Islamic Azad University, Lorestan, Iran.



Leila Jafari pour has graduated in MSc Program of Anatomical Science in Zahedan University of Medical Sciences, Zahedan, Iran. Her technical skills are Renal Ischemia Reperfusion in Rat and Renal histopathological changes follows Renal Ischemia Reperfusion and Nephrotoxicity.

Article info:

Received: 17 Dec 2012

Accepted: 20 Feb 2013

ABSTRACT

Introduction: Renal Ischemia Reperfusion is considered to be one of the causes of acute renal failure (AKI). In addition, renal ischemia is an important incident usually occurs due to renal transplantation, repair of suprarenal aneurysm, hemorrhagic shock. A recent study reported that reactive oxygen species (ROS) are important mediators of AKI. It seems essential to use antioxidant to decrease the effect of free radicals. The olive leaf extract (OLE) has an abundant antioxidant characteristic. The purpose of this study was to investigate the effects of olive leaf extract on the control of renal injuries caused by renal Ischemia-Reperfusion in an animal model.

Methods: forty male Sprague-dawley rats were randomly divided into 5 equal groups: control, I/R+ 0.5 ml water by gavages, I/R+OLE in 3 different doses (25mg/kg, 50mg/kg, 100mg/kg) once daily for 2 week, prior to I/R. The right and left pedicles clamped for 45 minutes (ischemia), followed by 24 hours of reperfusion. Serum BUN and Creatinine were measured, and serum malondialdehyde(MDA) was determined, renal histologically parameters such as tubular necrosis, eosinophilic casts were studied semi quantitatively and tubular dilatation was measured by motic image plus 2 software, and renal antioxidant enzyme activity such as Glutathione was assessed.

Results: I/R group significantly increased serum Cr and BUN, serum MDA, and tubular necrosis, casts, tubular dilatation, and significantly decreased Glutathione compared with the control group. Pretreatment with OLE+I/R in 3 different doses significantly decreased tubular dilatation, tubular necrosis and casts, serum MDA, and increased Glutathione compared with the I/R group. But only 4 group significantly decreased serum Cr and BUN compared with the I/R group.

Conclusion: The findings showed that two week pretreatment of rats with OLE by gavages in its three doses (25mg/kg, 50mg/kg and 100mg/kg) can ameliorate renal injuries compared with I/R group. In order to consider the effects of all antioxidant of OLE in decreasing caused by I/R further researches recommended.

Key Words:

Ischemia-Reperfusion,
Rat,
Olive Leaf Extract.

* Corresponding Author:

Leila Jafari pour, PhD

MSc in Anatomical Science, Zahedan University of Medical Sciences Zahedan, Iran.

Tel: 06614211785 / Fax: 06614212473

E-mail: elahejafari62@gmail.com

1. Introduction

Renal Ischemia Reperfusion (RIR) is considered to be one of the causes of Acute Renal Failure (ARF) [1-3]. Renal ischemia is an important incident usually occurs due to renal transplantation, heminephrectomy, and repair of suprarenal aneurysm, hemorrhagic shock, cardiac arrest and heart failure [1-4]. The produced Reactive Oxygen Species (ROS) of subsequent renal reperfusion causes injury of the protein, lipids, DNA and mitochondria and subsequently organ injury and apoptosis [5-7]. Injury or disfunction of protective antioxidant mechanisms during reperfusion is considered to be one of the causes of ischemia-reperfusion injury [8]. With the increase during ischemia, an advanced injury can be observed in the protective antioxidant of kidneys [9]. To decrease the effect of free radicals, using antioxidants seems to be essential. On the one hand, synthetic antioxidants such as butylated hydroxyanisole, butylated hydroxytoluene and hydroquinone show negative effects, so the use of natural antioxidants so much has been considered [10]. On the other hand, the use of medical plants has a special place in traditional medicine and they used to treat many ailments from many years ago. One of these plants is olive that its leaf extract has both antibacterial and antiviral characteristic playing and has an important role in decreasing the blood pressure and blood sugar[11]. Olive leaf extract is a kind of medical plant extract that is known for its antioxidant characteristics among different sections of olive tree. Olive's leaf is the richest source of phenolic compounds showing antioxidant characteristics [12].

Regarding the effective role of natural antioxidants in decreasing the tissue injuries caused by I/R and as artificial antioxidants, they lead to harmful side effects, the olive leaf has an abundant antioxidant characteristic. In this study, the effects of olive leaf extract on the control of renal injuries caused by renal Ischemia-Reperfusion in an animal model were investigated.

2. Materials & Methods

In this study, all of the animal experiments carried out in accordance with the National Institute of Health guide line or in accordance with the guides for care and use of laboratory animals.

2.1. Preparation of Ethanolic Olive Leaf Extract

The olive leaves (olea, europaea, and variety of sevilano) were collected from khoram abad in lorestan prov-

ince, Iran. Then, they were weighed and washed. The air-dried leaves were grinded into fine powder and the powder extracted with 1 liter of 80% ethanol at a temperature of 40 °C. On the basis of its dose, the extract in a required amount was dissolved, to be administered orally to the animals. Using HPLC method, the oleuropein amount of this extract was measured [13]. Its amount was reported as 13.57%.

2.2. Experimental Group

In this experimental study, forty male Sprague-dawley rats (10-11 weeks) weighing 200-250 g were kept at a room temperature of 24±1 °C and a humidity of 50±10 % with 12 hour light/dark cycle in the animal lab of Razi Herbal Medicines Research Center. In this study, the rats were randomly divided into 5 equal groups. Light per each group as follows: 1) control group 2) I/R group, only received 0.5 ml water by gavage daily without any treatment. 3) I/R group treated with OLE, 25 mg/kg. 4) I/R group treated with OLE, 50 mg/kg. 5) I/R group treated with OLE, 100 mg/kg. The olive leaf extract was administered to rats by gavage for 2 weeks.

2.3. Surgical Procedure

Two weeks after treatment with OLE, the animals were anesthetized intraperitoneally by injection of 60 mg/kg ketamine and 2.5 mg/kg diazepam, respectively. Then, the abdominal region of rats were shaved and sterilized with povidoneiodine solution. A midline laparotomy incision made from superior to the symphysis pubic to the tip of xiphoid process, and then the ultimate region was exposed [14-17]. To observe the kidneys located in the retro peritoneal region, the intestines were isolated [17]. Then both left and right pedicles were occluded bilaterally with two microvascular clamps [17]. The clamps were put bilaterally for 45 min not to damage the vascular [2]. During this period of time, the color of kidney turned pale and confirmed renal ischemia. 45 min after of ischemia, the clamps removed from pedicle region to consider the kidneys for 5 min until their color turned brown; this change of kidney color confirmed the reperfusion. During 45 min of ischemia, both intestines and kidneys were conserved with humid, hot and sterilized gauze.

2.4. Biochemical Analysis

24 hours after reperfusion, through anesthesia, the blood samples were taken of rats' right ventriculums and then centrifuged with 3000 rpm for 10 minutes and their serums separated. Left kidney was homogenized to mea-

sure the renal anti-oxidant enzyme such as Glutathione (GSH) with Phosphate Buffered Saline (PBS). Then, it was centrifuged with 5000 rpm at 4°C for 15 minutes and its supernatant used to measure the Glutathione.

2.5. Serum Parameters

Creatinine, blood urea nitrogen (BUN), serum were measured by autoanalyzer. MDA serum was performed manually through reaction with thiobarbituric acid (TBA). In this method, the amount of MDA was measured by spectrophotometric (532nm). MDA level was expressed as nmol/ml

2.6. Renal Biochemical Parameter

The amount of GSH was measured by Korkmaz et al's method. GSH level was expressed as nmol/mg protein [18].

2.7. Renal Histologic Analysis

24 hours after reperfusion, the right kidney of rat was put in formalin 10% for histology techniques. After sectioning the kidney tissues with microtome, the sections painted with hematoxylin and eosin. The histopathological changes were analyzed in Axiovision 40 from each kidney with magnification 400x with regard to tubular necrosis, tubular dilatation and eosinophilic casts. Tubular necrosis and eosinophilic casts regarded semiquantitative as follow: no damage = 0, mild = 1; unicellular,

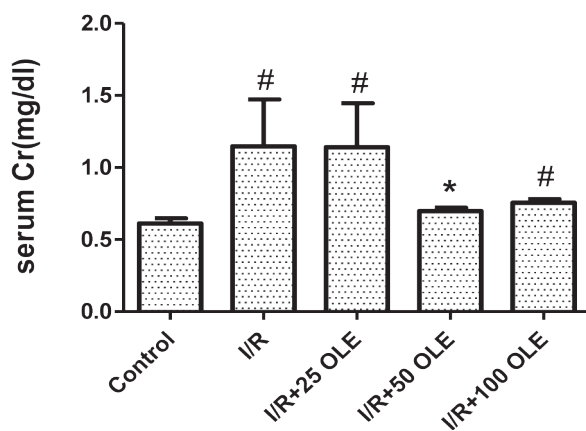
patchy isolated, moderate = 2; damage less than 25%, severe = 3; damage between 25-50%, very severe = 4; more than 50% damage [19]. The result of each parameter was reported separately. With regard to tubular dilatation, intra diameter of proximal tubule was measured by Motoc image plus 2 software in Axiovision 40 from each kidney.

2.8. Statistical Analysis

The data were expressed according to the mean and the standard error of mean. The group differences performed by Mann-Whitney test and statistical significances were at the 5% level (p value < 0.05). Using the SPSS software version 16, the statistical analyses were performed.

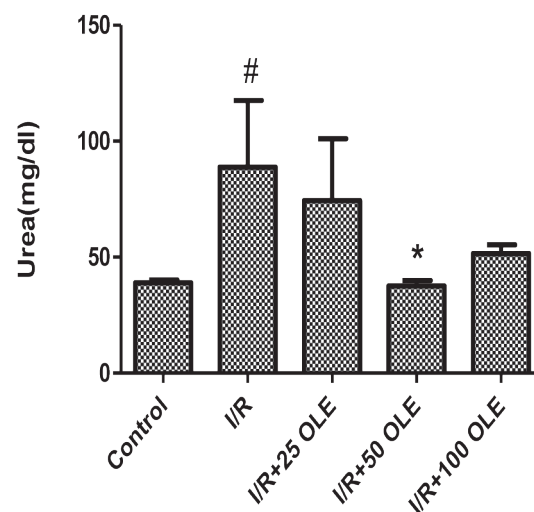
3. Result and Kidney Function

I/R group in comparison with control group, the creatinine level was significantly increased (p= 0.002). Only in three groups of OLE receivers the amount of serum was decreased compared to I/R group. However, the only group of OLE 50 mg/kg, namely, group 4, was significantly different from I/R group (p= 0.021) (Fig. 1A). Compared to control group, serum BUN of IR group was significantly increased (p= 0.028). The three groups treated with OLE compared to I/R group could reduce serum BUN, but only group 4 was significantly different from I/R group (p= 0.01). The BUN level was similar to the control group (Fig. 1B).



ANATOMICAL SCIENCES

Figure 1A. Note, Values are expressed as the Means ± SEM: * P<0.05 as compared with I/R # P<0.05 as compared with control



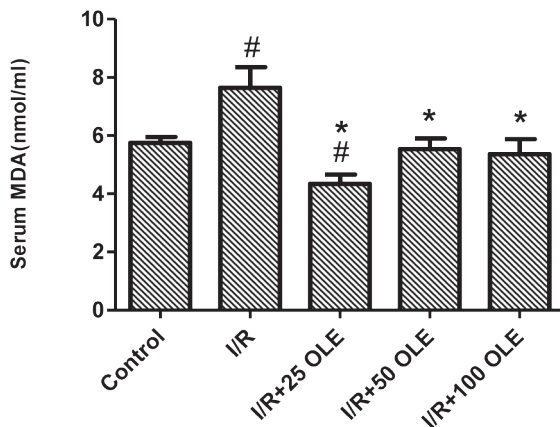
ANATOMICAL SCIENCES

Figure 1B. Note, Values are expressed as the Means ± SEM: * P<0.05 as compared with I/R # P<0.05 as compared with control

3.1. OLE and Biochemical Tests

In comparison with control group, the serum MDA in I/R group was significantly increased (p=0.038). Pretreatment with OLE could significantly decrease the amount of serum MDA in three groups of OLE receivers (p< 0.05). The amount of serum MDA was the same in group 1, 4 and 5 (Fig. 1C).

The GSH in I/R indicated a significant decrease compared to the control group (p=0.0). Pretreatment with OLE led to a significant increase in GSH in groups 3, 4 and 5 compared to I/R group (p< 0.05). Regarding the amount of GSH, no significant difference was observed between groups 1, 3, 4 and 5 (Fig. 1D).

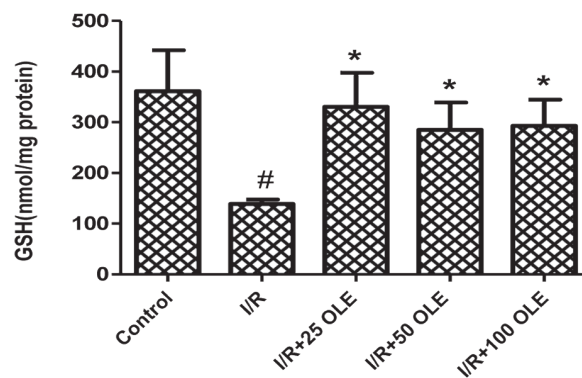


ANATOMICAL SCIENCES

Figure 1C. Note, Values are expressed as the Means ± SEM: * P<0.05 as compared with I/R # P<0.05 as compared with control

3.2. OLE and Histologic Result

In comparison with control group, tubular necrosis was significantly increased in I/R group (p= 0.0). Pretreatment with OLE in the three groups (25mg/kg, 50mg/kg and 100 mg/kg) could reduce significantly tubular necrosis compared to I/R group (p < 0.05) (Fig.2, Table.1). Tubular dilatation in I/R group was significantly increased compared to control group (p= 0.0). In all groups of OLE receiver (3, 4, 5), the intra diameter of proximal tubule was significantly decreased compared to I/R group. The intra diameter of proximal tubule of the three groups treated with OLE was similar to intra diameter of the control group (Fig.2, Table.1).



ANATOMICAL SCIENCES

Figure 1D. Note, Values are expressed as the Means ± SEM: * P<0.02 as compared with I/R # P<0.02 as compared with control

Table 1. Effect of olive leaf extract (OLE) on kidney tissue of kidney after renal I/R

Experimental Group	Tubular Necrosis	Eosinophilic Casts	Tubular Dilatation
Control	0.44±0.052	0.37±0.052	63.93±2.02
IR	1.39±0.037#	1.37±0.129#	90.59±4.35#
IR+OLE(25mg/kg)	0.79±0.084#*	0.63±0.095#*	70.25±3.21*
IR+OLE(50mg/kg)	0.8±0.085*	0.48±0.062*	68.03±3.42*
IR+OLE(100mg/kg)	0.76±0.115*	0.6±0.089*	71.23±4.88*

Note. Values are expressed as the Means±SEM

*P< 0.01 as compared with I/R

P< 0.05 as compared with control

ANATOMICAL SCIENCES

Control group ($p=0.0$). Pretreatment with OLE could reduce the amount of casts in the three groups of OLE receivers ($p<0.05$). Regarding the eosinophilic casts, there was no significant difference between groups 1, 4 and 5 (Fig.2, Table.1).

4. Discussion

The results of this study indicate that 45 minutes Ischemia followed by 24 hours Reperfusion can lead to an acute dysfunction in the kidney of rat. It was revealed that two weeks pretreatment of rats with OLE by gavage in its three doses (25mg/kg, 50mg/kg and 100mg/kg) can ameliorate kidney function, renal injuries and increase the activity of renal antioxidant enzymes compared with I/R group. Acute tubular necrosis occurs after ischemia [20]. Reperfusion regarded as an acute position for organs and it may enhance the injuries caused by ischemia [21].

The I/R injury caused by ROS can be estimated by such index as MDA [6, 18, 21]. However, injury or dysfunction of antioxidant protective mechanisms in the time of reperfusion considered as one of the reasons of I/R injuries [8, 21]. In the present study, antioxidants such as ETS-GS [7], erdosteine [22], mesna [23] recognized as effective factor in decreasing the injuries caused by I/R that is likely due to the decrease of intracellular ROS.

On the other hand, OLE includes known antioxidants such as oleuropein, tyrosol, caffeic acid, hydroxy tyrosol. Hydroxy tyrosol and oleuropein have powerful antioxidant characteristic and are able to remove ROS and reinforce antioxidant system of kidney [11, 24]. Therefore, it seems that antioxidants in olive leaf extract can diminish renal injuries caused by I/R.

The result of this study indicates that serum BUN and Cr in I/R group was significantly increased. Considering serum BUN and Cr as functional indicators of kidney, it was revealed that the kidney functional injury can be due to the increase of their densities lead to [25]. The other research reported the effect of diverse antioxidants on the decrease of both serum BUN and Cr [6, 7, 22, 23].

In the present study, serum MDA changed to ameliorate the renal function. It seems that the decrease MDA using OLE is due to its antioxidant characteristic in reducing both ROS and lipids peroxidation. In other studies, the antioxidant characteristic of OLE in decreasing the MDA was reported [24].

In this study, the amount of renal antioxidant enzymes activity such as GSH I/R group was significantly diminished compared with control group, that confirmed the results of the other studies, significantly decreased GSH [18]. The results of this study demonstrate a significant increase in amount of GSH in OLE-received groups compared with I/R group. The results of the present study are confirmed by the similar studies on diverse antioxidant [18].

An increase in amount of enzyme antioxidant such as GPX, Catalase, Glutathione and superoxide dismutas (SOD) in gentamicin-induced through pretreatment with OLE by Tavafi et al [24] reported an increase in amount of GPX, Catalase and SOD in cisplatin-induced through pretreatment with OLE by Biranvand et al [11]. According to these reports, antioxidant system of organ may be reinforced by OLE.

Based on some reports, ROS causes injury in renal epithelial tubular cells and induces apoptosis in these cells. In addition, the studies showed that antioxidant compounds cause removing of free radicals; therefore, they have protective effects on injury caused by I/R process [26, 27].

So it can be concluded that I/R cause increasing in amount of tubular necrosis in kidney tissue [1, 3, 28]. The results of this study indicated that three doses of OLE cause significant decrease in tubular necrosis, dilatation and casts eosinophilic compared with I/R group. According to other researchers' reports on OLE, OLE plays an effective role in decreasing tubular necrosis and tissue injuries caused by Genamicin-induced nephrotoxic [24]. It can be concluded that due to its antioxidant characteristic, OLE may reduce injuries of kidney tissue.

Two weeks pretreatment of rats with OLE by gavage in its three doses (25mg/kg, 50mg/kg and 100mg/kg) can ameliorate renal injuries and increase renal antioxidant enzymes activity compared with I/R group. In order to consider the effects of all antioxidant of OLE in decreasing caused by I/R, further researches are recommended.

Acknowledgements

The authors would like to appreciate the Razi Herbal Drugs Re-search Center of Lorestan Medical University for their Financial Support.

References

1. Tirapelli LF, Barione DF, Trazzi BF, Tirapelli DP, et al. Comparison of two models for evaluation histology of experimental renal ischemia. *Transplantation Proceeding*, 2009; 41: 4083-4087.
2. Linkun H, Cheng Y, Tian Z, Ming X, et al. Erythropoietin ameliorates renal ischemia and reperfusion injury via inhibiting tubulo interstitial inflammation. *Journal of Surgical Research*, 2011; 06: 1-7.
3. Dorai T, Fishman AL, Ding C, et al. Amelioration of renal ischemia-reperfusion injury with a novel protective cocktail. *The Journal of Urology*, 2011; 186: 2448-2454.
4. Defraigne JO, Pincemail J, Detry O, Fra-nssen C, Meurisse M, Limet R. Variations of glu- tathione and vitamin E concentrations after hyp- othermic storage in Euro-Collins solution and reperfusion of the rabbit kidney. *Transplant. Proc* 1995; 27: 2783-2785.
5. Kusaka J, Koga H, Hagiwara S, Hasegawa A, et al. Age-dependent responses to renal ischemia-reperfusion injury. *Journal of Surgical Research* , 2012; 172: 153-158.
6. Koga H, Hagiwara S, Kusaka J, Goto K, et al. New α -lipoic acid derivation, DHL-HisZn, Am- eliorates renal ischemia-reperfusion injury in rat. *Journal of Surgical Research*, 2011; 1-7.
7. Hagiwara S, Koga H, Iwasaka H, Kudo K, et al. ETS-GS, a new antioxidant, ameliorates renal ischemia-reperfusion injury in a rodent model. *Journal of Surgical Research*, 2011; 171: 226-233.
8. Polat C, Tokyo I, Kahraman A, Sabuncuoglu B, Y Imaz S. The effects of desferrioxamine and quercetin on hepatic ischemia-reperfusion induced renal disturbance. *Prostaglandins Leukot and Essent Fatty Acids* 2006;74(6):379-83.
9. Rajan D, Wu R, Shah KG, Jacob A, Coppa GF, Wang P. Human ghrelin protects animals from renal ischemia-reperfusion injury through the vagus nerve. *Surgery*, 2012; 151: 37-47.
10. Karthikumar S, Vigneswari K, Jegatheesan K. Screening of antibacterial and antioxidant activities of leaves of *Eclipta prostrata* (L). *Scientific Research and Essay* 2007; 2 (4), 101-104.
11. Beiranvand A, Rasouljan B, Alirezai M, Hashemi P, et al. Pretreatment with olive leaf Extract partially attenuates cisplatin-induced nephrotoxicity in rat. *Yafteh*, 2010 ; 11(5) : 35-44.
12. Rafiei Z, Jafari SM, Alami M, Khomeiri M. Antioxidant Properties of Olive Leaf Extract and its Application in Sunflower Oil . *Research Journal of Food*, 2011; 21(1) : 11-23.
13. Hashemi S, Delfan B, Ghiasvand A, Raeisi F, Alborzi M. Study of the amount of oleuropein level in the leaves of olive varieties cultivated in khorrabad (Iran). *Yafteh*, 2009; 10 (4): 98-106.
14. Awad AS, El-Sharif AE. Curcumin immune-mediated and anti-apoptotic mechanisms protect against renal ischemia/reperfusion and distant organ induced injuries. *International Immunopharmacology*, 2011; 11: 992-996.
15. Liu M, Gu M, Xu D, Lv Q, Zhang W, Wu Y. Protective effect of toll-like receptor 4 inhibitor eritoran on renal ischemia-reperfusion injury. *Transplantation Proceedings*, 2010; 42: 1539-1544 .
16. Xiaozhou He, Xianlin Xu, Min F, Xiao Ch, Xuejun S, et al. Preconditioning with hyperbaric oxygen induces tolerance against renal ischemia-reperfusion injury via increased expression of heme oxygenase-1. *Journal of Surgical Research*, 2011; 170: e271-e277.
17. Rajan D, Wu R, Shah KG, Jacob A, et al. Human ghrelin protects animals from renal ischemia-reperfusion injury through the vagus nerve. *Surgery*, 2012; 151: 37-47.
18. Korkmaz A, Kolankaya D. Protective effect of rutin on the ischemia/reperfusion induced damage in rat kidney. *Journal of Surgical Research*, 2010; 164: 309-315.
19. Kobuchi Sh, Shintani T, Sugiura T, Tanaka R, Suzuki R, et al. Renoprotective effects of γ -aminobutyric acid on ischemia/reperfusion induced renal injury in rats. *European Journal of Pharmacology*, 2009; 623: 113-118.
20. Oruc O, Inci K, Aki FT, Zeybek D, et al. Sildenafil attenuates renal ischemia reperfusion injury by decreasing leukocyte infiltration. *Acta histochemia*, 2010; 112: 337-344.
21. Cicora F, Lausada N, Vasquez DN, Cicora P, et al. Sirolimus in kidney transplant donors and clinical and histologic improvement in recipients: rat model. *Transplantation Proceedings*, 2010; 42: 365-370.
22. Gurel A, Armutcu F, Cihan A, et al. Erdosteine improves oxidative damage in a rat model of renal ischemia-reperfusion injury. *Eur Surg Res* 2004;36(4):206-9.
23. Mashiach E, Sela S, Weinstein T, et al. Mesna: A novel renoprotective antioxidant in ischemic acute renal failure. *Nephrol Dial Transplant* 2001;16(3):542-51.
24. Tavafi M, Ahmadvand H, Toolabi P. Inhibitory effect of olive leaf extract on gentamicin-induced nephrotoxicity in rat. *Iranian Journal Kidney Disease*, 2012; 6: 25-32.
25. Najafi A, Kadkhodae M, Seifi B, Delavari F, et al. Evaluation of protective effects of postconditioning on ischemia/reperfusion-induced acute kidney injury. *Pejouhandeh*, 2011; 15(6): 280-286.
26. Sadeghnia HR, Boroushaki MT, Mofidpour H. Effect of safranal on lipid peroxidation level during renal ischemia-reperfusion injury in rat. *Iran J Basic Med Sci*, 2005; 8: 179-185.
27. Seth P, Kumari R, Madhavan S, Singh A, et al. Prevention of renal ischemia-reperfusion-induced injury in rats by picroliv. *Biochemical Pharmacology*, 2000; 59: 1315-1322.
28. Koga H, Hagiwara S, Mei Hideto, Hiraoka N, et al. The vitamin E derivative, ESeroS-GS, attenuates renal ischemia-reperfusion injury in rats. *Journal of Surgical Research*, 2011;1-6.