

# The Arterial Pattern of Terminal Branch of the Abdominal Aorta in the Male Persian Squirrel (*Sciurus Anomalus*)

Ghasem Akbari<sup>1\*</sup>, Hasan Gilanpour<sup>2</sup>, Mohammad Babaei<sup>2</sup>

1. Department of Basic Sciences, Faculty of Veterinary Medicine, University of Tabriz, Tabriz, Iran.

2. Department of Basic Sciences, Faculty of Veterinary Medicine, University of Tehran, Tehran, Iran.

**Citation:** Akbari Gh, Gilanpour H, Babaei M. The Arterial Pattern of Terminal Branch of the Abdominal Aorta in the Male Persian Squirrel (*Sciurus Anomalus*). *Anatomical Sciences*. 2016; 13(2):125-130..



Dr Ghasem Akbari is assistant professor of Veterinary Anatomy. He was graduated from University of Urmia (DVM) and Tehran University (DVSc). He is working as an instructor in Department of Basic Sciences, Faculty of Veterinary Medicine, University of Tabriz, Tabriz, Iran. His research interests include development embryos, animal model nutrient, histology, anatomy and imaging anatomy.

## Article info:

Received: 04 Dec. 2015

Accepted: 21 Mar. 2015

Available Online: 01 Jul. 2016

## ABSTRACT

**Introduction:** The Persian squirrel (*Sciurus anomalus*) is considered the only well-known species of the family Scuridae in the Middle East. Since some people keep this squirrel as a domestic pet, their attendance at veterinary clinics is increasing. So far, no study has been conducted on the arterial supply of the pelvic cavity and limb in the squirrel. Hence, this research was performed to fill this gap.

**Methods:** Out of 5 adult male Persian squirrels, 2 were used for obtaining the Rhodopas cast and 3 for red-latex injection. To this end, after opening the abdominal cavity, Rhodopas and red-latex were injected into their aortae after branches to the renal arteries to specify their pattern of distribution in the pelvic region and limbs.

**Results:** The abdominal aorta in the pelvic region bifurcates into right and left common iliac arteries. Each common iliac artery is divided into the internal and external iliac arteries. The external iliac artery branches off from pudendoepigastric trunk and lateral circumflex femoral artery. Then this artery in the femoral canal continues as femoral artery branching the medial circumflex femoral, genicular, saphenous arteries and continues as popliteal artery. The internal iliac artery, after branching the umbilical artery, ramifies into 4 branches; cranial gluteal, caudal gluteal, urogenital, and finally the internal pudendal artery as the last branch.

**Conclusion:** The origins of the median sacral, obturator, and cranial gluteal arteries in Persian squirrel are considerably different from other rodents and small mammals.

## Key Words:

Aorta, Artery, Pelvic region, Persian squirrel, Rhodopas cast

## \* Corresponding Author:

Ghasem Akbari, PhD

Address: Department of Basic Sciences, Faculty of Veterinary Medicine, University of Tabriz, Tabriz, Iran.

Tel: +98 (41) 36378743

E-mail: g.akbari@tabrizu.ac.ir

## 1. Introduction

According to Baker [1], the Persian squirrel (*Sciurus anomalus*) is regarded as the only well-known species of the family Sciuridae in the Middle East. This wild species could be found in coniferous and temperate mixed forests in Armenia, Azerbaijan, Georgia, Greece, Iraq, Iran, Jordan, Lebanon, Palestine, Syria, and Turkey [2]. Also, some people keep this squirrel as a domestic pet. Therefore, their attendance at veterinary clinics is increasing [3].

The internal iliac artery (II), internal pudendal artery (IP), as well as umbilical (UA) and prostatic (PA) (or vaginal) arteries, which are derived from the former two arteries, constitute the main arterial supplies to the organs in the pelvic cavity [4, 5]. The arterial structure may differ among not only diverse species but also animals from the same species. Morphological approaches related to the vascular system are found useful for surgical interventions, experimental investigations, and teaching anatomy [6-8].

Possessing a profound knowledge of the vascular system can facilitate experimental investigations. By means of vascular catheters, inserted into the femoral artery (FA), researchers can take fluid samples or inject required materials when it is deemed necessary [9, 10].

Thus far, a myriad of studies exploring the arterial supplies to the organs in the pelvic cavity have been performed [11-13]. Their results indicate the distribution of the internal and external iliac arteries (EI) in the pelvis. Moreover, most studies have attempted to clarify the general supply pattern [14-16]. So far, no study has been conducted on the arterial supply of the pelvic cavity and hind limbs in the squirrel. Hence, the current research was conducted to fill this gap.

## 2. Materials and Methods

In the present study, 5 adult male Persian squirrels (*Sciurus anomalus*) were used. They were obtained from veterinary clinics and had no cardiovascular diseases. Their average weight was between 267 g and 290 g. To observe the arteries of the pelvic region, the latex-injection and Rhodopas cast methods were applied.

Two samples were used to provide the Rhodopas cast. First, the abdominal region was cut open. Then, the Rhodopas (AX-90-10-Rhone-Poulenc-Company) was injected into the end of the abdominal aorta by using 24-gauge angiocath. Afterwards, the injection site was ligated. To

coagulate the cast, the samples were kept in water for one hour. Next, they were immersed in 10% sodium hydroxide to corrode the soft tissues and obtain the Rhodopas casts. In three samples, after opening the abdominal cavity, the colored latex was injected into the aorta after branches of the renal arteries. Immediately afterwards, the injected samples were kept in 10% formalin until further studies were conducted. Then, they were carefully dissected under a dissecting microscope (ScanOptics-SO5800) and various vascular branches were specified and photographed with a digital camera (Canon SX1-IS).

## 3. Results

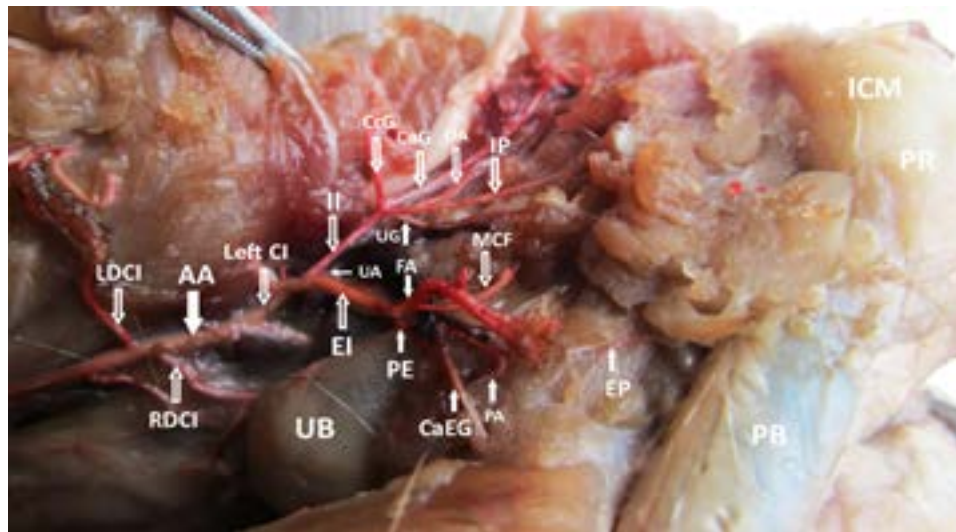
After studying the samples, it was recognized that the abdominal aorta (AA) finally bifurcated into the right and left common iliac arteries (CI). The deep circumflex iliac artery (DCI), in Persian squirrel, emerges from caudal abdominal aorta before the aortic bifurcation and the median sacral artery (MD) branched off from the left common iliac artery (Figure 1). At a distance of 0.5 cm, the common iliac artery bifurcated into the internal and external iliac arteries (Figure 2).

### The branches of the internal iliac artery

The internal iliac artery ramified into 4 branches after branched off the umbilical artery. First, the cranial gluteal artery (CrA) separated from it and ran to the pelvic region. Another branch separating from it and moving to the end of the ureter, ductus deferens, and bladder was the urogenital artery (UG). Next, the internal pudendal (IP) and caudal gluteal (CaA) arteries separated. The caudal gluteal artery passed through the greater sciatic notch and together with the sciatic nerve approached the dorsolateral side. Then, along with the sciatic nerve, below the deep gluteal muscle and the origin of the biceps femoris, it moved to the caudal side and set up branches in the relevant muscles. Moreover, one of its branches went to the tail and rectum. The rest of this branch reached the caudal surface of the ischiocavernosus muscle. The obturator artery (OA) separated from the internal pudendal artery and together with the obturator vein and nerve moved to the obturator foramen (Figures 1, 2).

### The branches of the external iliac artery

The lateral circumflex femoral artery (LCF) arose from the cranial side of the external iliac artery and the pudendoepigastric trunk (PE) arose from its caudomedial side. The latter artery bifurcated into the caudal epigastric (CaEG) and external pudendal arteries (EP). The external pudendal artery supplied blood to the scrotum and prepuce and extended to the penile root. In the middle of



ANATOMICAL SCIENCES

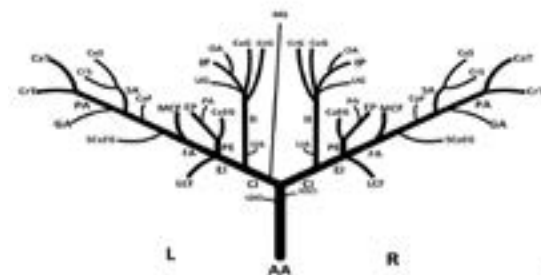

**Figure 1.** Left lateral view of pelvic cavity and limb arteries in latex injection method in Persian squirrel.

UB: Urinary Bladder, PR: Penile Root, PB: Penile Body, ICM: IschioCavernosus Muscle, AA: Abdominal Aorta, LDCI: Left Deep Circumflex Iliac artery, RDCI: Right Deep Circumflex Iliac artery, Left CI: Left Common Iliac artery, II: Internal Iliac artery, EI: External Iliac artery, UA: Umbilical Artery, CrG: Cranial Gluteal artery, CaG: Caudal Gluteal artery, IP: Internal Pudendal artery, OA: Obturator Artery, UG: UroGenital artery, PE: PudendoEpigastric artery, CaEG: Caudal EpiGastric artery, EP: External Pudendal artery, PA: Prostatic Artery, FA: Femoral Artery, MCF: Medial Circumflex Femoral artery.

this artery, a branch separated and went to the prostate and urethra. The branch is called prostatic artery (PA). Subsequent to the separation of the pudendoepigastric trunk and lateral circumflex femoral artery, the external iliac artery entered the femoral canal and continued there under the name of femoral artery (FA) (Figures 1, 2).

The medial circumflex femoral artery (MCF), as the first branch of the femoral artery, extended to the muscles

of the caudal thigh and hip joint. The superficial caudal epigastric (SCaEG) and caudal femoral arteries (CaF) in the middle of the thigh arose from the femoral artery individually. Distal to the superficial caudal epigastric artery and proximal to the knee, the femoral artery bifurcated into the saphenous and popliteal arteries. The saphenous artery (SA) was divided into cranial and caudal branches. It was observed that there existed a considerable distribution of small vessels arising from the saphenous



ANATOMICAL SCIENCES

**Figure 2.** Dorsal view of pelvic cavity and limb artery in Persian squirrel. (a) Rhodopas cast method, (b) Schematic view.

AA: Abdominal Aorta, LDCI: Left Deep Circumflex Iliac artery, RDCI: Right Deep Circumflex Iliac artery, CI: Common iliac artery, II: Internal Iliac artery, EI: External Iliac artery, MS: Median Sacral artery, UA: Umbilical Artery, CrG: Cranial Gluteal artery, CaG: Caudal Gluteal artery, IP: Internal Pudendal artery, OA: Obturator Artery, UG: UroGenital artery, PE: Pudendo-Epigastric artery, CaEG: Caudal EpiGastric artery, EP: External Pudendal artery, PA: Prostatic Artery, LCF: Lateral Circumflex Femoral artery, FA: Femoral Artery, MCF: Medial Circumflex Femoral artery, SCAEG: Superficial Caudal EpiGastric artery, CaF: Caudal Femoral, SA: Saphenous Artery, CrS: Cranial Saphenous artery, CaS: Caudal Saphenous artery, GA: Genicular Artery, PA: Popliteal Artery, CrT: Cranial Tibial artery, CaT: Caudal Tibial artery.

nous artery at the distal part of the medial thigh muscles, including the medial hamstring and adductor muscles. Running laterally between the adductor and quadriceps muscles, the popliteal artery (PA) moved toward the popliteal fossa. Close to the origin of the popliteal muscle, there was the genicular artery (GA) supplying blood to the distal part of the quadriceps femoris muscle. In the end, it was observed that the popliteal artery bifurcated into the cranial (CrT) and caudal tibial (CaT) arteries at the origin of popliteal muscle (Figure 2).

#### 4. Discussion

In the current study, the arterial anatomy of the Persian squirrel's pelvic cavity was examined in detail to develop a framework for its inner and collateral circulations. As for the pelvic region, the arrangements found in Persian squirrel were consistent with the general pattern in other mammals, where the internal iliac artery corresponds to the long pudendal artery [17] and shows a rather constant branching pattern.

The abdominal aorta ended by bifurcating into the common iliac arteries in the lumbar region. Generally, from the left common iliac artery, the unpaired median sacral artery arises. However, Ventura and López-Fuster [18] indicated that the median sacral artery was separated from the right common iliac artery in the talpidae. In addition, the median sacral artery stems from the terminal portion of the aorta or from the aortic bifurcation in dormouse [19] and wood mouse [20]. Furthermore, Pinto e Silva and Martins [21] carried out a study on opossum and stated that the middle sacral artery arose from the right common iliac artery in 30% of cases and from the left one in 30% of cases. Moreover, in 40% of cases, it was a continuation of the abdominal aorta. In general, the cranial gluteal artery arises from the internal iliac artery. Nevertheless, in dormouse [19], murine [22] and degu [13], the difference is that this artery branches off from the common iliac artery. In the present study, the caudal gluteal artery of the Persian squirrel originates from the internal iliac artery. However, based on some other studies, it arises from the common iliac artery [22].

In this context, the obturator artery stems from the internal pudendal artery. Nonetheless, this artery in degu [13] and the Mediterranean pine vole [12] branches off from the internal iliac artery. Moreover, the studies on guinea pig by Stump and Shively [23] and hamster by Rerkamnuaychoke et al. [24] demonstrated that this artery derived from the internal iliac artery through a common trunk with internal pudendal artery.

The umbilical artery of the Persian squirrel branches off at the origin of the internal iliac artery and it is the first branch of the internal iliac artery before dividing this artery into the cranial gluteal, caudal gluteal, internal pudendal, and urogenital arteries. These findings are similar to those in the studies by Stump and Shively [23] on guinea pig, by Erdogan [25] on domestic tomcat, and by Ventura and López-Fuster [19] on dormouse. However, the umbilical artery arises from the external iliac artery in the Mediterranean pine vole [12].

The deep circumflex iliac artery in Persian squirrel branches off from the caudal abdominal aorta before the aortic bifurcation. This finding is similar to the one about dormouse [19], pine vole [12], and degu [13]. However, the deep circumflex iliac artery in guinea pig [23] originates from the dorsal side of the external iliac artery.

According to our findings, the medial circumflex femoral artery in Persian squirrel branches off from the femoral artery. This is concurrent with the finding of Ventura and López-Fuster (1994) about dormouse. In addition, this artery is a branch of the femoral artery in *Sorex* and of the internal iliac artery in *Crocicidura* [18]. However, the medial circumflex femoral artery branches off from the external iliac artery in degu [13]. Furthermore, as a different pattern, the medial circumflex femoral artery in the Mediterranean pine vole originates from the pudendoepigastric trunk [12].

Similar to guinea pig [23], dormouse [19], the Mediterranean pine vole [12], degu [13], and murine [22], the external iliac artery in Persian squirrel gives rise to pudendoepigastric trunk, a short trunk dividing into the caudal epigastric and external pudendal arteries. However, there is a main difference in some cases of talpidae, in which the pudendoepigastric trunk can also stem from the initial portion of the internal iliac artery [18].

The external pudendal and caudal epigastric arteries in the common pudendoepigastric trunk arise from the external iliac artery. In Persian squirrel, this pattern is similar to the one in guinea pig [23], hamster [24], the Mediterranean pine vole [12], degu [13], dormouse [19], and talpidae [18].

The lateral circumflex femoral artery branches off from the cranial side of the external iliac artery at the ramification site of the pudendoepigastric trunk. However, in degu [18] and talpidae [18], this artery is a branch of the femoral artery. Moreover, in the long-tailed chinchilla (*Chinchilla lanigera*) [26], the lateral circumflex femoral artery stems from the femoral artery in a common trunk with the superficial caudal epigastric artery. There is a

considerable difference in dormouse, where the lateral circumflex femoral artery originates from the internal iliac or common iliac or cranial gluteal artery [19].

In the end, it must be emphasized that this was the first study on the arterial vascularization of the pelvic cavity and hind limb of the Persian squirrel. There are some differences between the vascular pattern of the Persian squirrel and that of other rodents. The origins of the median sacral, obturator, and cranial gluteal arteries in Persian squirrel is considerably different from others. In this study, the arteries and their origins in the pelvic region of the Persian squirrel were determined.

### Acknowledgements

The authors acknowledge the assistance of Dr. Masoud Adibmoradi. This paper had not any financial support.

### Conflicts of Interests

The authors declared no conflict of interest.

### References

- [1] Baker A. The Status and Distribution of the Persian Squirrel, *Sciurus anomalus* (Mammalia: Rodentia: Sciuridae), in Dibbeen Nature Reserve, Jordan. *Zoologische Abhandlungen* (Dresden). 2006; 55:199-207.
- [2] Harrison DL, Bates PJ. The mammals of Arabia. New York: Harrison Institute Publication; 1991.
- [3] Khazraiaia P, Rostami A, Haddadzadeh HR, Nassiri SM. Hematological characteristics and hemoglobin typing of the Persian Squirrel (*Sciurus anomalus*). *Journal of Exotic Pet Medicine*. 2008; 17(1):44-48. doi: 10.1053/j.jepm.2007.12.008
- [4] Nickel R, Schummer A, Seiferle E. The anatomy of the domestic animals. Hamburg: Verlag Paul Parey Publication; 1981.
- [5] Constantinescu GM. Veterinary anatomy of domestic mammals: Textbook and colour atlas. Hamburg: Schattauer Publication; 2004.
- [6] Hirata Y, Umemura K, Kondoh K, Uematsu T, Nakashima M. Experimental intimal thickening studies using the photochemically induced thrombosis model in the guinea-pig femoral artery. *Atherosclerosis*. 1994; 107(1):117-24. doi: 10.1016/0021-9150(94)90147-3
- [7] Kondo K, Suzuki Y, Ikeda Y, Umemura K. Genistein, an isoflavone included in soy, inhibits thrombotic vessel occlusion in the mouse femoral artery and in vitro platelet aggregation. *European Journal of Pharmacology*. 2002; 455(1):53-7. doi: 10.1016/s0014-2999(02)02449-4
- [8] Okada T, Harada T, Bark DH, Mayberg MR. A rat femoral artery model for vasospasm. *Neurosurgery*. 1990; 27(3):349-56. doi: 10.1227/00006123-199009000-00002
- [9] Bandoh T, Mitani H, Niihashi M, Kusumi Y, Ishikawa J, Kimura M, et al. Inhibitory effect of fluvastatin at doses insufficient to lower serum lipids on the catheter-induced thickening of intima in rabbit femoral artery. *European Journal of Pharmacology*. 1996; 315(1):37-42. doi: 10.1016/s0014-2999(96)00573-0
- [10] Georgiadis GS, Lazarides MK, Didilis VN, Mikroulis DA, Bougioukas GI. Treatment of femoral artery thrombosis following intra-aortic balloon insertion leaving the catheter in place. *Journal of Cardiovascular Surgery*. 2003; 44(1):149-50. PMID: 12627091
- [11] Nitschke T, Preuss F. Main branches of the internal iliac artery in man and domestic mammals in a comparative anatomical study. *Anatomischer Anzeiger*. 1970; 128(5):439-53.
- [12] Ventura J, López-Fuster MJ, Gispert E. Blood supply to the abdominal and pelvic regions in the Mediterranean pine vole, *Microtus duodecimcostatus* (Rodentia, Arvicolidae). *Anatomia, Histologia, Embryologia*. 1995; 24(2):133-37. PMID: 8588705
- [13] Ventura J, Gispert E, López-Fuster MJ. Arterial vascularization of the abdominal and pelvic regions in the degu, *Octodon degus* (Rodentia, Octodontidae). *Annals of Anatomy*. 1996; 178(3):285-91. doi: 10.1016/s0940-9602(96)80072-0
- [14] Carvalho RG, Souza WM, Prada IL, Souza NT. About the arterial blood vessels pelvic opossum's (*Didelphis albiventris*) behaviour. *Anatomischer Anzeiger*. 1989; 170(5):367-72. PMID: 2400113
- [15] López-Fuster MJ, Ventura J, Gispert E. The arterial system of the wood mouse, *Apodemus sylvaticus*: the pelvic region. *Anatomia, Histologia, Embryologia*. 1993; 22(3):279-87. doi: 10.1111/j.1439-0264.1993.tb00366.x
- [16] Fătu C, Puișoru M, Fătu IC. Morphometry of the internal iliac artery in different ethnic groups. *Annals of Anatomy*. 2006; 188(6):541-46. doi: 10.1016/j.aanat.2006.05.016
- [17] Schummer A, Wilkens H, Vollmerhaus B, Habermehl KH. The circulatory system, the skin, and the cutaneous organs of the domestic mammals. In: Nickel R, Schummer A, Seiferle E, editors. *The Anatomy of the Domestic Animals*. Berlin: Paul Parey pub; 1981, p. 126-83.
- [18] Ventura J, López-Fuster MJ. The blood supply to the abdominal and pelvic regions in talpids: character analysis and implications for specific relationships among Insectivora. *Annales des Sciences Naturelles-Zoologie*. 1998; 19(1):63-72. doi: 10.1016/s0003-4339(98)80135-4
- [19] Ventura J, López-Fuster MJ. The arterial system of the abdominal viscera and the pelvis of the dormouse, *Eliomys quercinus* (Gliridae, Rodentia). *Annals of Anatomy*. 1994; 176(4):327-31. doi: 10.1016/s0940-9602(11)80509-1
- [20] Jose M, Fuster L, Ventura J. Arrangement of the branches of the aorta abdominalis in the wood mouse (*Apodemus sylvaticus*). *Anatomia, Histologia, Embryologia*. 1992; 21(2):146-51. doi: 10.1111/j.1439-0264.1992.tb00331.x
- [21] Pinto e Silva JR, Martins MR. Anatomical study of the abdominal aorta sacral rami of the opossum (*Didelphis*

- albiventris). *International Journal of Morphology*. 2004; 22(3):217-20. doi: 10.4067/s0717-95022004000300007
- [22] Kochi T, Imai Y, Takeda A, Watanabe Y, Mori S, Tachi M, Kodama T. Characterization of the arterial anatomy of the murine hindlimb: functional role in the design and understanding of ischemia models. *PLoS One*. 2013; 8(12):e84047. doi: 10.1371/journal.pone.0084047
- [23] Stump JE, Shively MJ. The systemic arterial pattern of the guinea pig: the pelvis and pelvic limb. *American Journal of Anatomy*. 1976; 147(2):193-201. doi: 10.1002/aja.1001470204
- [24] Rerkamnuaychoke W, Kurohmaru M, Nishida T. The arterial supply of the male reproductive system in the hamster. *Anatomia, Histologia, Embryologia*. 1988; 17(4):301-11. doi: 10.1111/j.1439-0264.1988.tb00568.x
- [25] Erdogan S. Distribution of the arterial supply to the lower urinary tract in the domestic tom-cat (*Felis catus*). *Veterinárni Medicína*. 2011; 56:202-208.
- [26] Eken E, Besoluk K, Teke BE. An anatomical study on the conformation of the femoral artery in *Chinchilla lanigera*. *Revue de Médecine Vétérinaire*. 2005; 156(10):506-508.