

Protective Effect of Tribulus Terrestris Hydroalcoholic Extract against Cisplatin – Induce Apoptosis on Testis in Mice

Zahra Keshmand^{1*}, Ali Ghanbari², Raziye Keshmand³

1. PhD in Animal of Physiology, Department of Biology, Faculty of Basic Sciences, Science and Research Branch, Islamic Azad University, Tehran, Iran.

2. Assistant Professor in Anatomical Sciences, Fertility and Infertility Research Center, Kermanshah University of Medical Sciences, Kermanshah, Iran.

3. MSc. in Physics, Department of Physics, Faculty of Science, Imam Khomeini International University, Qazvin, Iran.



Zahra keshmand received her B.A in the field of Biology, animal science from razi university in 2005. She completed her Ph.D degree in the field of biology, animal science, animal physiology in 2013 from Science and Research Branch, Islamic Azad University, Tehran. The topic of her thesis for Ph.D degree was "Protective Effect of Tribulus Terrestris Hydroalcoholic Extract against Cisplatin – Induce Spem Parameter and Testis Tissue in Mice".

Article info:

Received: 20 Nov. 2013

Accepted: 23 Mar. 2014

ABSTRACT

Introduction: Cisplatin is an anti-cancer drug used in chemotherapy. One of the limiting side effects of cisplatin is decreasing genital gland function, azoospermia and oligospermia. Tribulus terrestris (TT) has been used as an aphrodisiac. The present study aimed to investigate the protective effect of TT hydroalcoholic extract against cisplatin-induced apoptosis on testis in mice.

Methods: Male adult mice (n=30) were divided into control group and 4 experimental groups (n=6). Control group received saline, the first experimental group received cisplatin (5.5 mg/kg) and other three experimental groups received cisplatin (5.5mg/kg) and different doses of hydroalcoholic extract of TT (100, 300 and 500 mg/kg/i.p) respectively. Day after the last injection, histopathology and histomorphologic analysis and also TUNEL assay on mice's testis were performed. Weights of body and testis, seminiferous tubules diameter and apoptotic index were assessed. Data analysis was performed using one-way ANOVA followed by Tukey's test.

Results: The results showed that cisplatin led to a reduction in the weight of body and testes, and increased apoptotic index significantly compared to the control group (P<0.001), while in treated groups with TT, the weights of body and testis and seminiferous tubules diameter were significantly higher compared with cisplatin group (P<0.001), but apoptotic index did not show significant differences.

Conclusion: The study demonstrates that extract of TT could have protective effect on cisplatin-induced apoptosis of testis and seminiferous tubules diameter that may be related to the presence of antioxidant components acting via a multitude of central and peripheral mechanisms.

Key Words:

Cisplatin, Tribulus terrestris, Apoptosis, TUNEL

* Corresponding Author:

Zahra Keshmand, PhD

Address: Department of Biology, Faculty of Basic Sciences, Science and Research Branch, Islamic Azad University, Tehran, Iran.

Tel: +98(918)7340515

E-mail: zkeshmand2001@yahoo.com

1. Introduction:

Cis-Diamminedichloroplatinum (II) (cisplatin) is one of the most effective anticancer agents for the treatment of patients with a wide spectrum of tumors. However, the use of a high dose of cisplatin is difficult in practice predominantly because of its strong side effects occurring in the reproductive tracts [13].

Cisplatin toxicity is occurred by increased production of reactive oxygen species (ROS) and decreased production of antioxidants [9]. The formation of ROS depends on the concentration of CDDP and the duration of exposure. ROS might reduce the capacities of the cell by DNA damage [7].

Tribulus terrestris (TT) herb has been commonly used in folk medicine to energize, vitalize and improve sexual function and physical performance in men. Although different effects of TT on animals and men have been evaluated and many active compounds from TT extract have been established, the mode of its action and efficacy remains uncertain and controversial. It is widely believed that TT affects strongly the androgen metabolism increasing significantly testosterone or testosterone precursor levels [14].

Studies show that Tribulus terrestris contains steroids, saponins, flavonoids, alkaloids, unsaturated fatty acids, vitamins, tannins, resins, nitrate potassium, aspartic acid and glutamic acid [18]. This plant has several advantages including antimicrobial, antibacterial, antioxidant and antitoxic activities and is used in the treatment of cardiovascular diseases, diabetes, tumors, articular pains and respiratory diseases [2].

The aim of the current study is to investigate the influence of TT extract on histological characteristics of testis. TUNEL assay was also performed for showing the occurrence of apoptosis in the testis.

2. Materials and Methods

Preparation of plant extract

T. terrestris was purchased from a traditional medicine center and identified and authenticated by a botanist. T. terrestris (400 g) were powdered and added to 800 cc of 70% ethanol and were left to macerate at room temperature for 4 hours. Then, the soaked seeds were extracted by percolation method and the obtained extract was concentrated in the vacuum and was dried

in the flat surface [20]. The weight of the obtained extract was 6.5 g. The extract was dissolved in distilled water and was immediately administered intraperitoneally (IP) to mice, it was expressed as mg of extract per kg of body weight and the injection was administered from day one for 4 days.

Drug

Cisplatin (EBEWE Pharma, Unterach, Austria) was dissolved in saline in darkness, 10-15 min before use and an intraperitoneal injection (5.5 mg/kg) was given at the first day of experiment [5].

Animals-inberd

Thirty male Balb/c mice with weight of 25-30 g were used. Animals were kept in the temperature of 22±2°C, under controlled environmental conditions, 12-hour light-dark cycles and fed with standard pellet chow and water ad libitum. All experiments procedures were conducted in accordance with the principles for the care and use of laboratory animals in research center and approved by local ethics committee of our university.

Experiment protocol

After a quarantine period of 7 days, 30 mice were randomly divided into five groups (n=6). Group I was used as control group and received saline intraperitoneally (I.P). Group II received only cisplatin in single dose of 5.5 mg/kg/ i.p. daily. Group III received cisplatin+ 100mg/kg extract of TT. Group IV received cisplatin+ 300 mg/kg extract of TT. Group V received cisplatin+500mg/kg extract of TT. Experimental groups were treated over period of 4 consecutive days.

After 4 days, pubertal mice of five groups were weighed and were anesthetized with ethylether and killed by decapitation. The testes were removed and weighed. Then, 5 µ m histological sections were achieved from paraffin blocks of left testes. The sections stained with Hematoxylin and Eosin and also with terminal deoxynucleotidyl transferase (TdT)-mediated deoxy-UTP nick end labeling (TUNEL) as previously described [8].

Morphometry

For this purpose we measured the external diameter and the lumen diameter of 150 seminiferous tubules per animal by fitting a graticule of a calibrated linear scale in the ×10 eyepiece of Leitz microscope at objective lens ×40 using of calibrated Motic software. For mea-

suring the tubular diameter was subtracted from luminal diameter [23].

Maturity of germ line epithelium

About 100 tubules per animal were evaluated for determining the maturity of germ line epithelium by X10 objective lens which was served for this propose [22].

TUNEL Assay

Apoptosis was assessed by terminal deoxynucleotidyl transferase (TdT)- mediated deoxy-UTP nick end labeling (TUNEL) assay by using In Situ Cell Death Detection Kit, AP (Roche Diagnostics Deutschland GmbH, Germany; 16848091).

The paraffin sections were dewaxed and rehydrated by standard methods. Proteases were added and incubated with 5% of appropriate normal serum for 30 min at 37C. The slides were washed in phosphate buffered saline (PBS). The sections were permeabilised (2 min, on ice) and incubated with TUNEL reaction mixture (60 min, 37C). Anti-fluorescein-AP was added and incubated (30 min, 37C). Contra staining was undertaken with propidium Iodide (PI; 1µg/ml-1). Apoptotic index (AI) was calculated by dividing the number of TUNEL-positive cells to total number of the cells in randomly focused fields, and the result was multiplied by 100 [21].

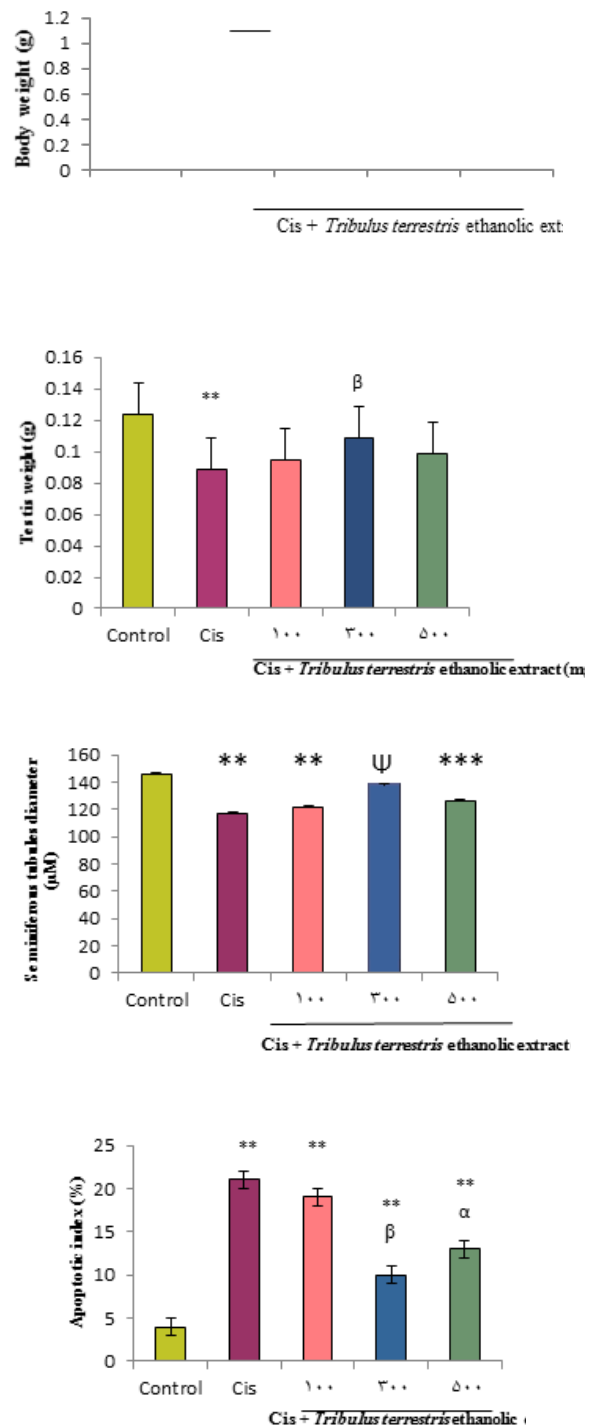
Statistical analysis

Values are expressed as mean \pm SD. Statistical analysis was performed by unpaired Student's t test and a significance was put at $P < 0.05$.

3. Results

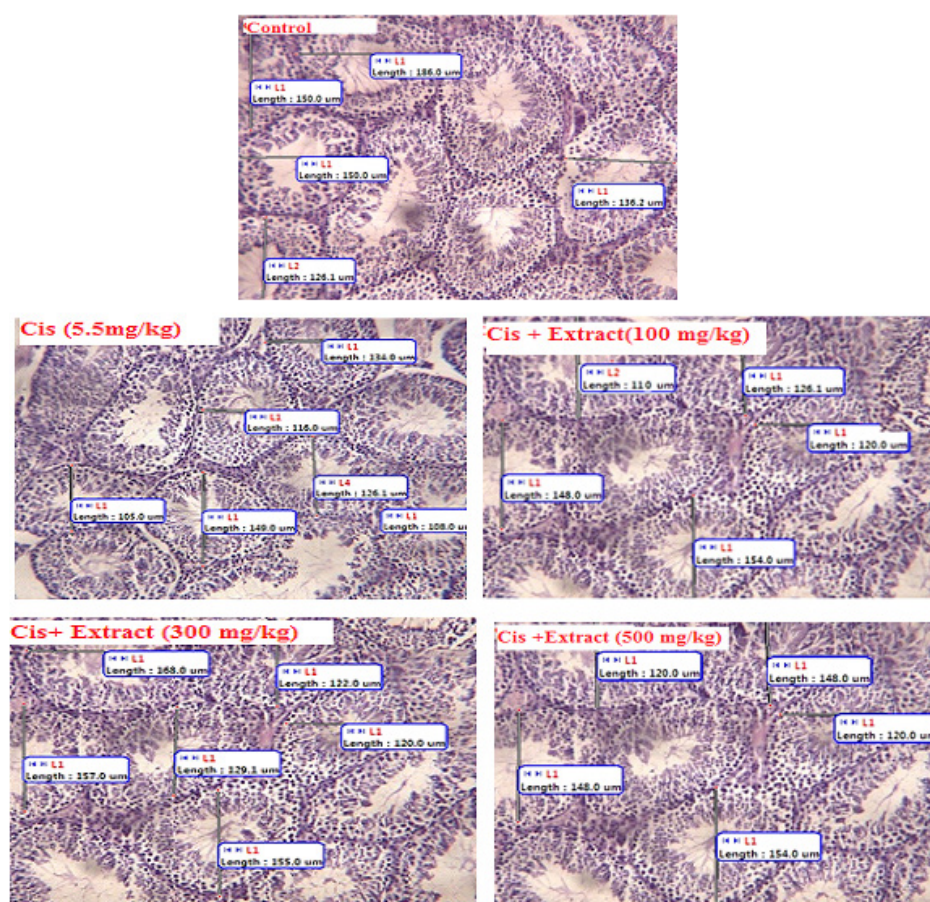
The mean of weights of body and testis had significantly decreased in E1 in comparison with control group ($P = 0.037$) but it increased significantly in group that received cisplatin+ 300 mg/kg extract of TT in comparison with cisplatin group ($P = 0.01$) (Figure 1A, B). Testicular sections showed that the diameter of the seminiferous tubules were reduced in cisplatin treated mice ($P = 0.001$) and seminiferous tubules diameter increased significantly ($P = 0.001$) in group that received cisplatin+ 300 mg/kg extract of TT group in comparison with cisplatin group (Figure 1C, 2).

TUNEL staining sections of the testis showed that both germ cells and Sertoli cells can be induced to apoptosis (Fig. 3) and evaluated apoptotic index of



ANATOMICAL SCIENCES

Figure 1. The effect of toxic dose of cisplatin (5.5 mg/kg) and different doses of *T. terrestris* on A: body weights (left bar of the pairs is initial weights and the right bar is end weights) ,B: testis weight, C: diameter of seminiferous tubules, D Apoptotic index.***The mean difference is significant at the 0.001 level in comparison to the control group. **The mean difference is significant at the 0.01 level, $\alpha = P < 0.05$ in comparison to the cisplatin group (5.5mg/kg/ day), $\beta = P < 0.01$ in comparison to the cisplatin group (5.5mg/kg/ day), $\psi = P < 0.001$ in comparison to the cisplatin group (5.5mg/kg/ day).



ANATOMICAL SCIENCES

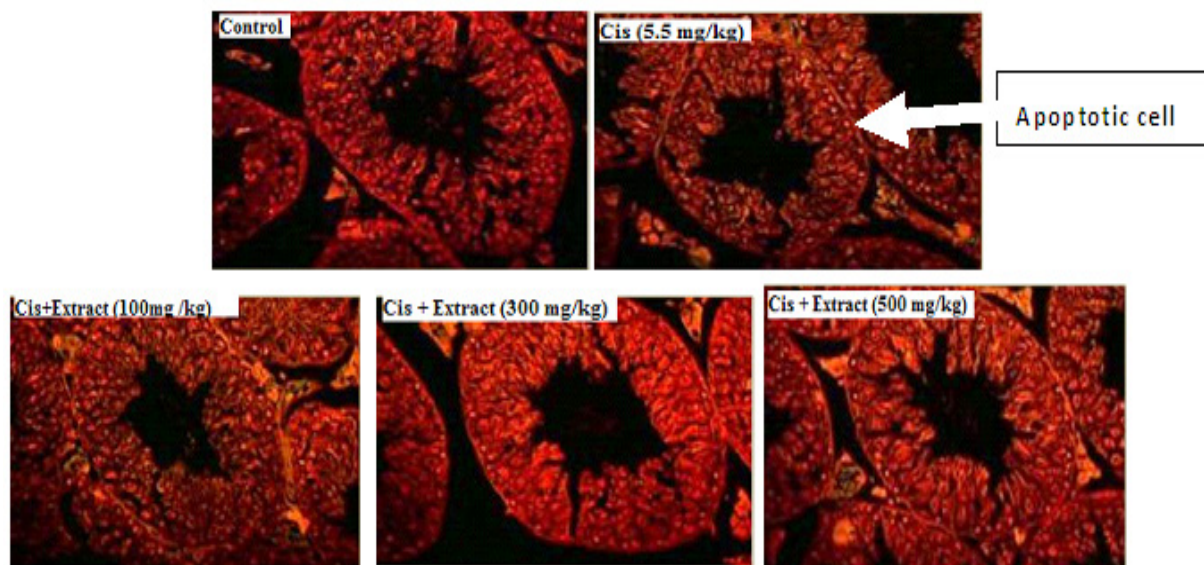
Figure 2. The effect of toxic dose of cisplatin (5.5 mg/kg) and different doses of Tribulus Terrestris on seminiferous tubules of balb/c mice (TUNEL staining, Arrow show TUNEL positive cells, X 120).

these sections presented significant increase in cisplatin group in comparison with control group ($P=0.001$) (Figure 1D,3).

4. Discussion

In the present study, protective effect of Tribulus terrestris hydroalcoholic extract on cisplatin-induced cytotoxicity in mice was evaluated. The results showed a significant declination in the weight of animals treated with cisplatin. These data support other studies that indicated reductions in body weight could be attributable to toxic side effect of chemotherapeutic drugs and it suggests that *T. terrestris* relieves the adverse effects of cisplatin [25]. The present study also showed histological damage in testis of mice after 4 days of injection of one cytotoxic dose of cisplatin. The results obtained from the present study revealed a remarkable increase in body weight and reproductive organs weight which were significantly higher than the controls after four days of treatment. Beside these therapies, herbal ex-

tracts have attracted the attention of many researchers for reducing the side effects of chemotherapeutic agents. This attenuation is based on the fact that free radicals that mediate reactions are responsible for a wide range of cisplatin induced side effects. Consequently, anti-oxidants have been shown to protect non-malignant cells and organs against damage by cisplatin [4]. This increase was possibly due to that treatment which affected the metabolic pathway towards hypoglycemic condition resulted in stimulation of growth hormone (GH) secretion from anterior pituitary gland that encourages secretion of insulin like growth factors "IGF-I and II" [16]. This hormone is necessary to stimulate skeletal muscle growth, regulate lipolysis and promote cellular uptake of amino acids [11]. This result is in agreement with result of other researchers who reported a significant increase in body weight of female mice [1], and male mice treated with TT extract. Insulin like growth factors I and II play important role in increasing protein synthesis and decreasing protein catabolism [24].



ANATOMICAL SCIENCES

Fig. 3. The effect of toxic dose of cisplatin (5.5 mg/kg) and different doses of Tribulus Terrestris on seminiferous tubules of Balb/C mice. Light microscopy of cross sections of H&E stained testis (Magnifications: X10).

The other possibility is that this increment may be due to the presence of some substance (s) in the extract that stimulates the regulation of fats and carbohydrates metabolism. It has been reported that TT may be a good appetizer and digestion promoter [10].

In the present study, apoptotic DNA fragmentation was determined in kidney and testis using the TUNEL technique. A single dose of cisplatin caused apoptosis in testes (germ cells and Sertoli cells). The high rate of apoptosis in the present study suggests that apoptosis is an important mechanism of toxicity of cisplatin. Chemotherapy leads to single and double DNA strand breaks, most often followed by cell death. Recent studies have shown the important role of apoptosis in the pathogenesis of cisplatin testicular [3,19].

Thus, together with other herbal extracts, tribulus terrestris reduces apoptosis of cisplatin by decreasing the number of apoptotic cells that can be considered as the antioxidant activity or diuretic effect of Tribulus Terrestris.

This increment may be caused by antioxidant activity of the extract or by some TT aqueous extract contents such as saponins (disgenin) and sterol (β -siosterol, stigma sterol) which contain phytoestrogen [6].

On the other hand, the active chemical in *T. terrestris* is likely to be protodioscin (PTN) [14]. The antioxidant activity of *T. terrestris* could be attributed to its flavonoidal content [17]. Flavonoids act as scavengers

of various oxidizing species i.e. super oxide anion ($O_2^{\bullet-}$), hydroxyl radical or peroxy radicals, they also act as quenchers of singlet oxygen [12].

In conclusion, treatment of male mice with extract of TT showed obvious effects on the testis studied. The four days period of treatment seems to be more effective on both testis and apoptotic index.

Acknowledgement

The authors appreciate the Kermanshah University of Medical Science research fund for providing us with financial support on this work by grant no. 9205. There is no conflict of interest in this study.

References

- [1] Abid NN. Effect of crude aqueous extract of Tribulus terrestris on some parameters of fertility in abino mice, [MSc. Thesis], Inst Emb Res and Infe Treat, Al-Nahrain University, Baghdad, Iraq; 2010; 12(2): 231-232.
- [2] Ahmed A H, Abbas A M, Heba H I, et al. Study the biological activities of Tribulus Terrestris extracts. Journal of Medical Engineering & Technology. 2009; 27(2): 433-435.
- [3] Arjumand W, Seth A, Sultana S. Rutin attenuates cisplatin induced renal inflammation and apoptosis by reducing NF κ B, TNF- α and caspase-3 expression in wistar rats. Food and Chemical Toxicology. 2013; 49(2): 2011-2017.

- [4] Atessahin A, Karahan Turk G, Gur S. Protective role of lycopene on cisplatin induced changes sperm characteristics, testicular damage and oxidative stress in rat. *Toxic Reports*. 2006; 21(1); 42-46.
- [5] Bagnis C, Beaufile H, Jacquiaud C, et al. Erythropoietin enhances recovery after cisplatin-induced acute renal failure in the rat. *Nephrology Dialysis Transplantation*. 2001; 16(3): 932-938.
- [6] Brinker F. Herbs contraindication and drug interaction. *Eclectic Medical Publications, Sandy, Ore (Internet)*; 1998; 25(3): 123-124.
- [7] Brozovic A, Ambriović-Ristov A, Osmak M. The relationship between cisplatin-induced reactive oxygen species, glutathione, and BCL-2 and resistance to cisplatin. *Critical Reviews in Toxicology*. 2010; 40(2): 347-359.
- [8] Chehreie S, Sadri S, Khazaei M, et al. Prenatal water deprivation induce apoptosis in sexual dimorphic nucleus of the brain of male new born Sprague-Dawley rats. *International Journal of Morphology*. 2011; 29(2): 496-500.
- [9] Chirino Y I, Pedraza-Chaverri J. Role of oxidative and nitrosative stress in cisplatin-induced nephrotoxicity. *Experimental and Toxicologic Pathology*. 2009; 61(3): 223-242.
- [10] Chopra RN, Nayar SL, Chopra IC. *Glossary of Indian medicinal plants (Including the supplement)*. Coun Scie & Indust Res, New Delhi. India; 1986.
- [11] Couchman GM, Hammond CB. *Physiology of reproduction*. Danforth's obstetrics and gynecology. Sott, J.R. (8th ed). Lippincott Williams and Wilkins. New York. London. Sydney; 1999; 8(2): 978-981.
- [12] Das NP, Pereira TA. Effects of flavonoids on thermal autoxidation of palm oil: structure activity relationships. *Journal of the American Oil Chemists' Society*. 1997; 67(5): 255-258.
- [13] Frezza M, Hindo S, Chen D, et al. Novel metals and metal complexes as platforms for cancer therapy. *Current Pharmaceutical Design*. 2011; 16(10): 1813-1825.
- [14] Gauthaman K, Ganesan AP. The hormonal effects of Tribulus terrestris and its role in the management of male erectile dysfunction: an evaluation using primates, rabbit and rat. *Phytotherapy*. 2006; 15(3): 44-54.
- [15] Gauthaman K, Adaikan PG, Prasad RN. Aphrodisiac properties of Tribulus terrestris extract (Protodioscin) in normal and castrated rats. *Life Sciences*. 2002; 71(12): 1385-1396.
- [16] Ganong WF. *The gonads development and function of the reproductive system* In: *Review of medical physiology* (22nd ed.). Lange Medical Books. McGraw- Hill; 2005; 22(2): 1237-1239.
- [17] Harborne JB, Williams CA. *Advances in flavonoid research since 1992*. *Phytochemistry*. 2000; 55(2): 481-504.
- [18] Karimi J, Malekzadeh H, Shiravani S, et al. Effect of the tribulus terrestris extract on spermatogenesis in the rat. *Journal of Jahrom University of Medical Sciences*. 2012; 9(4): 7-11.
- [19] Kang KP, Park SK, Kim DH et al. Luteolin ameliorates cisplatin-induced acute kidney injury in mice by regulation of p53-dependent renal tubular apoptosis. *Nephrology Dialysis Transplantation*. 2011; 26(3): 814-818.
- [20] Khazaei M, Salehi S. Protective effect of Falcaria vulgaris extract on ethanol- induced gastric ulcers in rat. *Iranian Journal of Pharmacology & Therapeutics*. 2006; 5(1): 1-4.
- [21] Lirdi LC, Stumpp T, Sasso-Cerri E, et al. Amifostine protective effect on cisplatin-treated rat testis. *Anatomy Research International (Hoboken)*. 2008; 291(7): 797-808.
- [22] Johnsen SG. Testicular biopsy score count: a method for registration of spermatogenesis in human testis. *Hormones*. 1970;1(1):2-25.
- [23] Orazizadeh M, Khorsandi LS, Hashemitabar M. Toxic effects of dexamethason on mous testicular germ cell. *Andrologia*. 2010; 42(4):247-253.
- [24] Tawfiq LJ. Effect of Tribulus terrestris extract on reproduction in mature male mice. [M.Sc. Thesis] Institute of Embryo Researches and Infertility Treatment, Al-Nahrain University; 2007; (1):97-103.
- [25] Yun JW, Shin ES, Cho SY, et al. Effects of BADGE and caffeine on the time-course response of adiponectin and lipid oxidative enzymes in high fat diet-fed C57BL/6J Mice: Correlation with reduced adiposity and steatosis. *Experimental Animals*. 2008; 57(2): 461-469.