

Case Report: Formation of Median Nerve by Three Roots

Mohammad Sadegh Gholami Farashahi ¹, Rahimeh Seifali ^{1*}, Ali Arab Kheradmand ²

1. Department of Anatomy, School of Medicine, Tehran University of Medical Sciences, Tehran, Iran.

2. Department of Surgery, Cancer Institute, Imam-Khomeini Hospital, Tehran University of Medical Sciences, Tehran, Iran.



Rahimeh Seifali was born in 1984. She received her B.A in the field of nursing, from Hamadan University of Medical science in 2007. She completed her MS degree in the field of Anatomy in 2013 from Isfahan University of Medical Science. Currently, she is studying as PhD student at Tehran University of Medical Science. She published two articles in national journals and presented three articles in several congresses.

Article info:

Received: 03 Mar. 2014

Accepted: 22 Jun. 2014

Key Words:

Brachial plexus, Median nerve,
Musculocutaneous nerve

ABSTRACT

Atypical connections in the formation of the brachial plexus are prevalent and have been reported in different articles. The present report describes a case of variation of the median nerve observed in the Iranian male cadaver during routine trial dissection. There are three roots for median nerve. Median nerve is formed by joining two lateral and medial cords of brachial plexus. Third root of median nerve which is carried by musculocutaneous nerve 3 cm of coracobrachialis muscle and then it is separated from musculocutaneous nerve but instead of joining median nerve, it pierces coracobrachialis muscle and outs from a place near entrance point and joins median nerve in middle arm and normally passes the rest of its passage. It is important for medical staff to be aware of this variation while planning a surgery in the region of axilla or arm, as these nerves are more susceptible to be injured during operations.

1. Introduction

The median nerve (MN) is a peripheral nerve in upper limb. MN consists of two branches of medial and lateral cord and descends downward in front of the arm and passes superficial to the brachial artery from lateral to medial side. It reaches the cubital fossa along with the brachial artery and it is placed inside the artery.

Routinely, it does not innervate any muscles in the arm. The musculocutaneous nerve (MCN) emanates from the lateral cord of brachial plexus then descends down and pierces coracobrachialis muscle (CB) to innervate it and also innervates brachial and biceps brachii muscles.

In forearm MCN innervates skin of the forearm through lateral cutaneous nerve of forearm without any link with

other nerves [1]. Atypical connections in the formation of the brachial plexus are common and have been reported in the articles [2, 3].

In this study, formation of median nerve by three roots was introduced in a case report.

2. Materials & Methods

This study was conducted on a male cadaver in Department of Anatomy, Medical School, Tehran University of Medical Sciences. The brachial plexuses were dissected carefully and the present variation was observed in the left upper limb.

3. Results

The present variation was observed in the left upper limb of male cadaver, during routine dissection in the anatomy

* Corresponding Author:

Rahimeh Seifali, PhD

Address: Department of Anatomy, School of Medicine, Tehran University of Medical Sciences, Tehran, Iran.

Tel: +98 (912) 9319209

E-mail: seyfielham@yahoo.com

department of Tehran University of Medical Sciences. According to survey performed about the left axillary fossa, it was observed that first root of Medial cord and second root of Lateral cord was normal and in distance of 5.5 cm of coracoid process joined together and made main trunk of MN. Third root of MN by MCN was carried from 3 cm distance of CB and was separated from MCN but instead of joining MN in the beginning it pierced CB and passed out the muscle at a point close to the entrance to CB muscle and joined to MN in Middle of arm. MN in the continuation of the path was in normal state (Figure 1). In addition, right axillary fossa in this cadaver was dissected, but nothing unusual was found. The right brachial plexus was normal (Figure 2)

4. Discussion

Unusual links between the MCN and the MN are the most common among all variations in brachial plexus [4]. Fibers of the MN transferred by the MCN, after short distance, leave the latter to join the main trunk [5]. Chauhan et al. (2002) have reported A third root (TR) of the MN emerged from the MCN and exactly joined the MN in 12.3 cm distal of the coracoid process, below the level of insertion of the CB. It was also reported that the MCN did not penetrate through CB [6], but in the present case MCN then bifurcates, both of which are entered to the CB. The links between the MCN and MN were classified and reported by Le Minor (1990) in five groups including [7]:

Type I: There are no connection fibers between the MCN and MN.

Type II: In this case, some fibers of medial root of MN are annexed with the lateral root of MN and constitute the main trunk of MN, the rest of the medial root fibers run in the MCN leaving it after a distance to join the main trunk of MN.

Type III: In this kind of variation the lateral root of the MN from the lateral cord is carried by MCN and separates it after a short distance and joins the main trunk of the MN.

Type IV: The fibers of the MCN adjoin with the lateral root of the MN. After some distance, the MCN separates from the MN.

Type V: The MCN is absent. The fibers of MCN transfer by the MN.

The variation in present case is analogous to type III variation of Le Minor.

Three kinds of connections between the MCN and MN in relation to the CB were only described by Venieratos and Anagnostopoulou (1998) including [4]:

Type I: link between MCN and MN (proximal to the entering the MCN into the CB),

Type II: This type is distal to the muscle

Type III: In this type, the muscle wasn't pierced by nerve and its communicating branch.




Figure 1. Left Upper Limb (Median Nerve With Three Roots): Median nerve (MN)- Musculocutaneous- nerve (MCN)- Coracobrachialis muscle (CBM)- First Root (FR)- Second Root (SR)- Third root (TR).

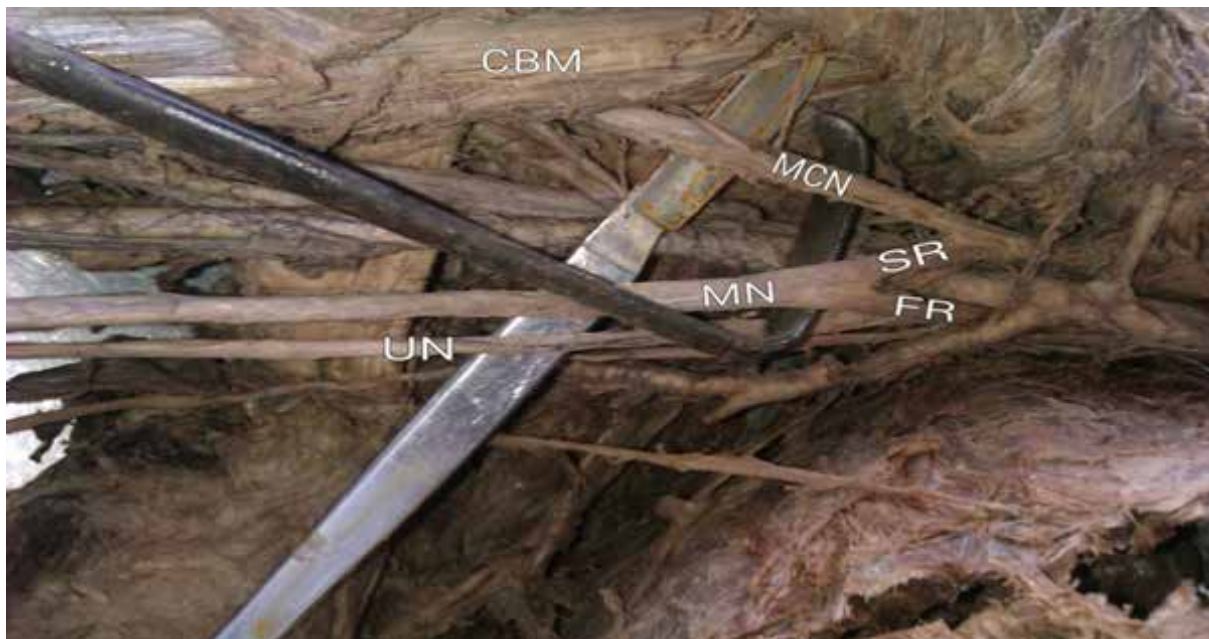


Figure 2. Right Upper Limb (Right Brachial Plexus is Normal)

ANATOMICAL SCIENCES

According to top division, case of our study can be placed in type I.

Comprehension and learning of such variations in clinical items such as dissections, post traumatic evaluations of the arm, nerve grafting and neurophysiological evaluation are very important.

Cases such as shoulder dislocations, fractures of Humerus, coracoid process grafting and shoulder arthroscopies may damage the MCN and MN in this regions [8].

In the embryologic processes, motor axons reach at the base of developing limb bud in the 5th week of Intra Uterine Life [9]. Growth cones advancement trend constitute brachial plexus in the upper limb. This advancement of growth cones is regulated by the expression of different factors in a specific fission [10]. This is the phase that is able to make different variations in brachial plexus.

This type of variations in the formation of brachial plexus is applied. Also, awareness of the normal and abnormal formation of brachial plexus should be considered by neurosurgeons to treat tumors and orthopedics for the cervical spine operations.

References

- [1] Standring S. Gray's anatomy. 40th ed. London: Churchill Livingstone; 2008, pp: 791-822.
- [2] Linell EA. The distribution of nerves in the upper limb, with reference to variabilities and their clinical significance. *Journal of Anatomy.* 1921; 55(Pt 2-3):79.
- [3] Kerr AT. The brachial plexus of nerves in man, the variations in its formation and branches. *American Journal of Anatomy.* 1918; 23(2):285-395.
- [4] Venieratos D, Anagnostopoulou S. Classification of communications between the musculocutaneous and median nerves. *Clinical Anatomy.* 1998; 11(5):327-31.
- [5] Williams PL, Bannister LH, Berry MM, Collins P, Dyson M, Dussek JE, Ferguson, MWJ. Gray's Anatomy In: Nervous system. 38th Edn; Churchill Livingstone. Edinburgh. 1995, pp: 1266-1274.
- [6] Chauhan R, Roy T. Communication between the median and musculocutaneous nerve—a case report. *Journal of the Anatomical Society of India.* 2002; 51(1):72-5.
- [7] Le Mniot J. A rare variant of the median and musculocutaneous nerve in man. *Archives of Anatomy, Histology & Embryology.* 1990; 73:33-42.
- [8] Flatow EL, Bigliani LU, April EW. An anatomic study of the musculocutaneous nerve and its relationship to the coracoid process. *Clinical Orthopaedics and Related Research.* 1989; 244:166-71.
- [9] Moore KL, Persaud TV. The musculocutaneous septum. 7th ed. Philadelphia; Saunders Elsevier; Before we are born. 2003, pp: 181-186.
- [10] Larson WJ. Development of peripheral nervous system. 3rd ed. Pennsylvania: Churchill Livingstone. Human Embryology. 2001, pp: 115-116.