

Case Report: The Anomalous Insertion of Pectoralis Minor (Le Double Type III): A Case Report



Adil Asghar^{1*}, Ravi Kant Narayan¹, Abhigyan Satyam¹, Padamjeet Panchal¹, Shagufta Naaz²

1. Department of Anatomy, All India Institute of Medical Sciences Patna (AIIMS Patna), Patna, India.

2. Department of Anaesthesiology, All India Institute of Medical Sciences Patna (AIIMS Patna), Patna, India.



Citation Asghar A, Narayan RK, Satyam A, Panchal P, Naaz S. The Anomalous Insertion of Pectoralis Minor (Le Double Type III): A Case Report. *Anatomical Sciences*. 2021; 18(1):45-50.



Article info:

Received: 25 Aug 2020

Accepted: 30 Nov 2020

Available Online: 01 Jan 2021

Keywords:

Ectopic, Anomalous, Pectoralis minor, Prevalence, Rotator cuff

ABSTRACT

Introduction: The pectoralis minor muscle originates from the third to fifth ribs of the chest wall and inserts at the medial side of the coracoid process of the scapula. It contributes to the abduction of the scapulothoracic joint and the downward movement of the shoulder. The anomalous insertion of pectoralis minor beyond the coracoid process is recognized since the 19th century. This study aimed to report the curious case of the anomalous insertion of pectoralis minor at greater tuberosity via rotator interval.

Case Report: A unilateral anomalous insertion of pectoralis minor muscle was found on the right side during the routine dissection of the upper limb in a sixty-year-old male cadaver. The anomalous attachment was present beyond the coracoid process which extended to the underneath of the coracoacromial ligament. After cutting the coracoacromial ligament, the tendon was located in the rotator interval, i.e., followed by its final insertion at greater tuberosity along with the tendon of the supraspinatus muscle. Three variations of anomalous tendon insertion were identified based on the classification of Le Double. In this case, type IIIM of Le Double classification was found; muscle belly (not tendon) crossed the coracoid process and attached at greater tuberosity. The muscle was separated from the coracoid process by a very thin bursa.

Conclusion: The pectoralis minor tendon may be found in the rotator interval, and surgeons should be careful during rotator cuff repairs.

* Corresponding Author:

Adil Asghar, PhD.

Address: Department of Anatomy, All India Institute of Medical Sciences Patna (AIIMS Patna), Patna, India.

Tel: +91 (991) 1225915

E-mail: dradilasghar2009@gmail.com

1. Introduction

The pectoralis minor is located in the pectoral region of the thoracic cage deep to the pectoralis major, extending from the rib cage to the coracoid process of the scapula [1]. It originates as 3 fleshy slips from the external surface of the third, fourth, and fifth ribs close to their costochondral joints [2]. The muscle is inserted on the superomedial border of the horizontal portion of the coracoid process. Variations in the insertion of Pectoralis Minor (PMi) have been described as surpassing PMi tendon from the coracoid process to attach at different sites. The coraco-humeral, coracoacromial ligament, glenoid rim, supraspinatus tendon, the capsule of the glenohumeral joint, and infraglenoid humeral tubercles are the reported sites of insertion [3]. Le Double observed anomalies in the PMi insertion and was the first to classify them by describing 3 types, as follows: Type I: only the tendon crosses the coracoid process and gets inserted on the above-mentioned sites. Type II: tendon and few muscle fibers crosses the coracoid process and gets inserted on the sites, as mentioned earlier. Type III: the whole muscle (and not merely the tendon) runs over the coracoid process and gets inserted on different sites discussed above (Figure 1A) [4]. This peculiar case is being reported as the anomalous insertion of PMi in the rotator interval at the greater tubercle along with the supraspinatus tendon in the dissected specimen.

2. Case Report

A unilateral anomalous insertion of PMi muscle on the right side during routine dissection of the upper limb was observed in a sixty-year-old male cadaver. The muscular belly of PMi was observed running over and beyond the coracoid process; it continued as a tendon underneath the coracoacromial ligament. The muscle was separated from the coracoid process by a very thin bursa without any groove or depression on the bone. Moreover, the surface was observed to be smooth and gleaming due to the presence of periosteum after removing the bursa. After cutting the coracoacromial ligament, the tendon was located in the rotator interval; subsequently, it was followed to its final insertion on the glenohumeral capsule between the gutter of the coraco-humeral ligament and supraspinatus muscle. Finally, the fibers of the tendon reached the greater tuberosity along with the tendon of supraspinatus (Figure 1B). Such an insertion of PMi was classified by Le Double as anomalous insertion type III,

i.e., least frequent. The muscle belly of PMi crossing the coracoid process, like type III was hitherto unreported.

The origin and innervation of pectoralis minor were usual without any distinguishing characteristics. The PMi of the left side presented no visible anomaly. Both shoulders were examined for movement. The lateral rotation was restricted by 27 degrees on manual passive rotation (right side: 58° & left side: 85°), i.e., measured by the goniometer. Other movements were almost similar on both sides. The anomalous muscle was taught in the lateral rotation and inferior translation of the right shoulder joint. Most of type III anomalous tendons reported in the literature were inserted either at coraco-humeral or coracoglenoid ligament; however, its attachment was uncharted at rotator interval.

3. Discussion

Gantzer was the first to report the insertion of PMi into the shoulder joint capsule, according to Asghar et al. (2021) [5]. Wood described that the anomalous tendon of PMi made a groove at the coracoid process. Besides, the tendon was blended in a fibrous capsule along with supraspinatus [6]. Macalister reported a case in which a distinct aponeurosis of the PMi tendon crossed the root of the coracoid process and wound downwards and outwards to insert onto the capsule of the shoulder [7]. Earlier observations concerning the insertion of the pectoralis minor have been referred to in the treatises of Testut and Le Double [4, 8]. Patten reported a case of bilateral capsular insertion of part of PMi [9].

The classification of Le Double was introduced based on the relation of the PMi tendon with the coracoid process [10]. Type III insertion of PMi reported by Lee et al. and Lee et al. were tendinous; however, in the present report, the muscle was crossing the coracoid process. The existing literature lacks reports regarding the relation of the muscular belly of PMi with the coracoid process. The reported prevalence of specific subtypes of Le Double was as follows: Type I: 7.7%-33.3% and type II: 5.7%-66.6% after combining the results of 640 shoulders documented by three authors: Schwarz and Hirtler, Lee, and Fang-Dschau [2, 11, 12].

Lee et al. reported 5 insertions of type III on Magnetic resonance (MR) arthroscopic evaluation of 335 shoulders (1.5%); four were tendinous and one was muscular while crossing the coracoid process [13]. However, Lee et al. documented a very high prevalence of type III in 74 dissected specimens (23.5%). It was either an incidental finding or type I insertion, counted as type III leading to a

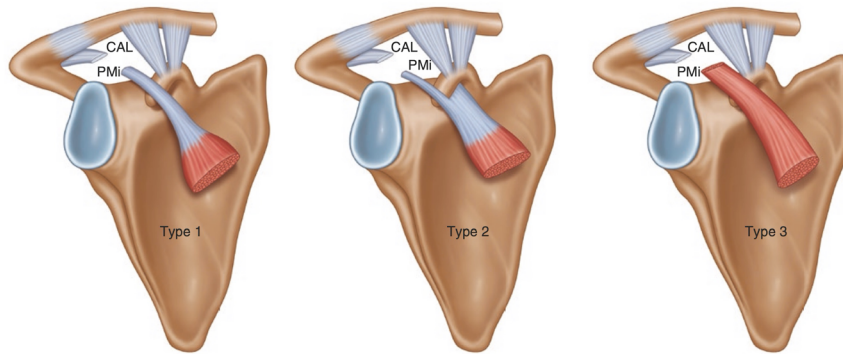


Fig1a The three types of variations of the superior attachment of the pectoralis minor muscle as described by Le Double. CAL coracoacromial ligament, PMi pectoralis minor.

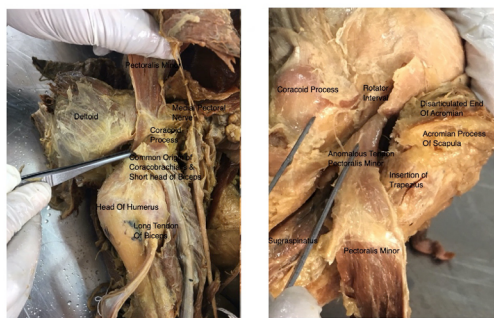


Fig1b

Insertion of Pectoralis minor traced up to greater tuberosity. The fibres of Pectoralis minor entered into rotator interval and finally attached to greater tuberosity along with anterior fibers of Supraspinatus and capsular fiber of glenohumeral joint (Shoulder Joint)

ANATOMICAL SCIENCES

Figure 1. A: Le Double classification of anomalous insertion of PMi; CAL-Coraco-acromian ligament, PMi-Pectoralis Minor **B:** Schematic diagram of anomalous insertion and the image of dissected shoulder joint showing the anomalous insertion of PMi.

The first end of forcep on the coracoid process and another end on the anomalous tendon of PMi.

lower prevalence of type I [10]. There were inconsistencies for types I and III of Le Double classification among authors. These data required minor modification to avoid undue confusion for the tendinous extension of PMi.

Aponeurotic or flattened tendinous extension after attachment at the coracoid process may be treated as type I. Type II required no modification. Two subtypes may be introduced in type III of Le Double classification, as type IIIT for tendon and type IIIM for muscle belly without any attachment at coracoid process. The tendon of PMi leads indentation on the superior surface of the coracoid process, i.e., considered a sign of anomalous tendon, even in the dried scapula [2]. Such indentation was absent when muscle lies over the coracoid process, as observed in the present report.

The overall prevalence of anomalous attachments (all types) of PMi varied from 11% to 79% in earlier studies. Macalister observed 17 anomalous tendons in 106 (16%) dissected specimens [7]. Whether the reference

is made to the number of bodies or of sides examined remains undiscovered. Wood found the abnormal tendon in 25 of 136 (18.8%) shoulders [6]. Several cases in which he found the pectoralis minor to insert into the clavicle were excluded. Kolts et al. reported a very high prevalence in the dissected specimen (79%) [14]. No extensive studies were conducted to observe the frequency of the extension of the tendon of the pectoralis minor beyond the coracoid process. The female and left-sided frequencies were higher than their opposites [4]. The radiological prevalence of the insertion of the ectopic PMi tendon was lower, because of failures to identify the tendons of PMi [10, 11].

Macalister argued that the coraco-glenoid ligament was a remnant of the more primitive humeral attachment of the pectoralis minor [7]. Sicarda believed that PMi gained attachment to the coracoid process, a superficial portion of the fibers persisted as the coracohumeral and coracoglenoidal ligaments in humans which was noted by Sicarda et al. (1938) [15]. Huntington concluded

that PMi insertion gradually migrated cephalad after series of dissections in mammals (especially the lemurs & marmosets, the lower monkeys, anthropoid apes, & humans). The humeral insertion of PMi was primitive, which had become capsular, then capsular and coracoid, finally entirely coracoid in mankind [16]. Conversely, Lander suggested that the coracoid insertion of the pectoralis minor could not be the secondary adaptation, as it is present in many of the very primitive mammals. It migrated during the embryological period to the humerus or another point of attachment [17].

Bland-Sutton had countered Lander's opinion and adopted the previous theory. Such a theory was supported by Tubbs et al. in a preview of the reverse correlation between the size of PMi insertion area and coraco-pectoral distance [1]. Homsy et al. reported a single case of type III anomalous insertion during MR arthroscopic evaluation of 335 shoulders [18]. It was inserted on the coracohumeral ligament; however, in the present report, it was inserted at greater tuberosity via capsular attachment (hitherto unreported).

Such anatomical variations were reported in the literature along with impingement syndrome or thoracic outlet syndrome or rotator cuff injury or compromised external rotation of the shoulder joint [19]. Pectoralis minor tenotomy is indicated for thoracic outlet syndrome or compromised lateral rotation at the shoulder due to the anomalous insertion of PMi. Pectoralis minor tendon is commonly used for the repair of the rotator cuff; however, its anomalous insertion complicated the techniques or compromised the rotation at the glenohumeral joint due to tightness [20]. The ectopic tendon, after releasing from the gleno-humeral capsule, is sutured with a lesser tubercle of the Humerus. Ectopic tendon attachment may hamper the fibrotic scar proliferation in rotator interval following rotator cuff repair. Furthermore, it may proceed as Superior Labrum Anterior to the Posterior (SLAP) lesion [3].

The shoulder pain and dyskinesia were reported in half a dozen case reports of anomalous insertion of PMi tendon. Few radiological studies documented that preoperative imaging, like Ultrasonography (USG) or Magnetic Resonance Imaging (MRI), provided less sensitivity in the detection of this pathology. This condition may lead to a more significant loss of Range of Motion (ROM) if attached to gleno-humeral capsule, compared to the coraco-glenoid or coraco-humeral ligament [11].

4. Conclusion

The strong relationship between the gleno-humeral capsule and ectopic insertion of PMi at the rotator interval may be associated with the loss of external rotation at the shoulder joint. This uncommon anatomic variation should be suspected if anterior shoulder pain presents or is triggered by forced passive external rotation even in asymptomatic patients. A prior musculoskeletal USG or MRI assessment should be considered to rule out the ectopic insertion of PMi in the repair of rotator cuff or tenotomy in impingement syndrome. If this unusual anomaly is detected, a tenotomy with or without the reimplantation of the PMi on the coracoid process should be performed to achieve adequate external rotation. Both phylogenetic and biomechanical studies could be conducted in the population to reveal the enigma of the ectopic insertion of PMi and their impact on rotator cuff biomechanics.

Ethical Considerations

Compliance with ethical guidelines

There were no ethical considerations to be considered in this research.

Funding

This research did not receive any grant from funding agencies in the public, commercial, or non-profit sectors.

Authors' contributions

All authors equally contributed in preparing this article.

Conflict of interest

The authors declared no conflicts of interest.

References

- [1] Tubbs RS, Oakes WJ, Salter EG. Unusual attachment of the pectoralis minor muscle. *Clinical Anatomy*. 2005; 18(4):302-4. [DOI:10.1002/ca.20113] [PMID]
- [2] Schwarz GM, Hirtler L. Ectopic tendons of the pectoralis minor muscle as cause for shoulder pain and motion inhibition: Explaining clinically important variabilities through phylogenesis. *PLoS One*. 2019; 14(6):e0218715. [DOI:10.1371/journal.pone.0218715] [PMID] [PMCID]

- [3] Ruiz Santiago F, Ruiz Tristán A, Butani P. Anomalous insertion of the pectoralis minor tendon at the greater tuberosity. *Journal of Ultrasound*. 2020; 23(3):407-10. [DOI:10.1007/s40477-019-00414-0] [PMID]
- [4] Le Double AF. [Treatise on variations of the muscular system of man and their significance from the point of view of zoological anthropology (French)]. Paris: Schleicher frères; 1897. [DOI:10.5962/bhl.title.44649]
- [5] Asghar A, Narayan RK, Satyam A, Naaz S. Prevalence of anomalous or ectopic insertion of pectoralis minor: A systematic review and meta-analysis of 4146 shoulders. *Surgical and Radiologic Anatomy (SRA)*. 2021; 43(5):631-43. [DOI:10.1007/s00276-020-02610-8] [PMID]
- [6] Wood J. XVII. Variations in human myology observed during the winter session of 1867-68 at King's College, London. *Proceedings of the Royal Society of London*. 1868; 16:483-525. [DOI:10.1098/rspl.1867.0110]
- [7] Macalister A. On muscular anomalies in human anatomy, and their bearing upon homotypical myology. *Proceedings of the Royal Irish Academy (1836-1869)*. 10(1866-1869):121-64. https://scholar.google.com/scholar?q=On+muscular+anomalies+in+human+anatomy,+and+their+bearing+upon+homotypical+myology&hl=fa&as_sdt=0,5
- [8] Testut L. [Muscle abnormalities in humans: Explained by comparative anatomy and their importance in anthropology (French)]. Paris: Librairie de l'Academie de Medecine; 1884. [DOI:10.5962/bhl.title.100796]
- [9] Patten CJ. Bilateral capsular insertion of part of the tendon of the pectoralis minor. *Journal of Anatomy*. 1934; 68(Pt 3):427. [PMID] [PMCID]
- [10] Lee KW, Choi YJ, Lee HJ, Gil YC, Kim HJ, Tansatit T, et al. Classification of unusual insertion of the pectoralis minor muscle. *Surgical and Radiologic Anatomy*. 2018; 40(12):1357-61. [DOI:10.1007/s00276-018-2107-0] [PMID]
- [11] Lee CB, Choi SJ, Ahn JH, Ryu DS, Park MS, Jung SM, et al. Ectopic insertion of the pectoralis minor tendon: Inter-Reader agreement and findings in the rotator interval on MRI. *Korean Journal of Radiology*. 2014; 15(6):764-70. [DOI:10.3348/kjr.2014.15.6.764] [PMID] [PMCID]
- [12] Dschau F. [A common insertion variety of the pectoralis minor muscle in the Chinese. Contribution to the racial anatomy of the Chinese (German)]. *Zeitschrift für Morphologie und Anthropologie*. 1937; 37(1):119-23. <https://www.jstor.org/stable/25749565>
- [13] Lee SJ, Ha DH, Lee SM. Unusual variation of the rotator interval: Insertional abnormality of the pectoralis minor tendon and absence of the coracohumeral ligament. *Skeletal Radiology*. 2010; 39(12):1205-9. [DOI:10.1007/s00256-010-0926-0] [PMID]
- [14] Kolts I, Busch LC, Tomusk H, Arend A, Eller A, Merila M, et al. Anatomy of the coracohumeral and coracoglenoidal ligaments. *Annals of Anatomy*. 2000; 182(6):563-6. [DOI:10.1016/S0940-9602(00)80105-3] [PMID]
- [15] Sicarda. [Anomalie de terminaison dn muscle petit pectoral (French)]. *Sa Signification*. 1930:352-5. [Link Not Found]
- [16] Huntington GS. Present problems of myological research and the significance and classification of muscular variations. *American Journal of Anatomy*. 1903; 2(2):157-75. [DOI:10.1002/aja.1000020202]
- [17] Lander KF. The pectoralis minor: A morphological study. *Journal of Anatomy*. 1918; 52(Pt 3):292-318. [PMID] [PMCID]
- [18] Homsí C, Rodrigues MB, Silva JJ, Stump X, Morvan G. [Anomalous insertion of the pectoralis minor muscle: Ultrasound findings (French)]. *Journal de Radiologie*. 2003; 84(9):1007-11. [PMID]
- [19] Low SCS, Tan SC. Ectopic insertion of the pectoralis minor muscle with tendinosis as a cause of shoulder pain and clicking. *Clinical Radiology*. 2010; 65(3):254-6. [DOI:10.1016/j.crad.2009.11.004] [PMID]
- [20] Higgins MA, Tambe A. Aberrant pectoralis minor tendon and surgery around the coracoid process. *Shoulder & Elbow*. 2012; 4(2):117-8. [DOI:10.1111/j.1758-5740.2011.00168.x]

This Page Intentionally Left Blank