

Research Paper: Auricle Morphometry in Iranian Population



Leila Elyasi^{1*}, Sanaz Araban¹, Seyed Hassan Eftekhari Vaghefi²

1. Department of Medical Anatomy, Faculty of Medicine, Kerman University of Medical Sciences, Kerman, Iran.

2. Neuroscience Research Center, Department of Anatomy, Faculty of Medicine, Golestan University of Medical Sciences, Gorgan, Iran.



Citation Elyasi L, Araban S, Eftekhari Vaghefi SH. Auricle Morphometry in Iranian Population. Anatomical Sciences. 2020; 17(2):47-54.



Article info:

Received: 02 Dec 2018

Accepted: 20 Apr 2019

Available Online: 01 Jul 2020

Keywords:

Auricle morphometry,
Anthropometry, Lobule

ABSTRACT

Introduction: Anthropometric measurements are useful in the surgery and diagnosis of congenital diseases. Also, these measurements could promote clinical efficiency. This study aimed to evaluate and compare the anthropometric measurements of the right and left auricles and determine the dominant type among both sexes of the Iranian population.

Methods: The study included 400 people (200 males and 200 females) aged 20-30 years, in Bandar Abbas City (south of Iran). We measured nine anthropometric parameters on both sides, in this population.

Results: In males, the mean values of the length of the auricle, the width of the auricle, the length of the concha, the width of the concha, cephalo-auricular angle, ear-skull distance, tragus-alar distance, nasal length, and the most common lobule shape were 59.86 mm, 30.71 mm, 24.32 mm, 17.83 mm, 57.63°, 8.71 mm, 101.72 mm, 50.31 mm, and round lobule, respectively, while in females were 60.12 mm, 31.36 mm, 25.32 mm, 17.73 mm, 55.68°, 8.40 mm, 101.36 mm, 40.76 mm, and round lobule, respectively. Also, we measured eight anthropometric parameters on both sides. The lop ear deformity rates in males and females were 10.5% and 7.8%, respectively.

Conclusion: The shape and dimensions of auricle considerably differ between diverse populations because of ethnicity, race, gender, age, and the use of different measurement methods. Also, the present result showed that the auricle dimension of males was less than that of females, but it was more symmetric in male subjects.

* Corresponding Author:

Leila Elyasi, PhD.

Address: Department of Medical Anatomy, Faculty of Medicine, Kerman University of Medical Sciences, Kerman, Iran.

Tel: +98 (911) 3932235

E-mail: elyasi_leila@yahoo.com

1. Introduction

Anthropometry is a science that studies human body characteristics, including length, circumference, width, and height [1], which are affected by gender, race, and nutrition [2]. This information can be used to design and improve the tools, equipments, workstations, and clothing items [1]. Anthropometric data can be gathered from dead or alive bodies [2]. Also, anthropometry is one of the simple, noninvasive, inexpensive, and universal ways to survey morphological structures [3, 4]. Therefore, with such a tool that can determine the standard dimensions, many musculoskeletal diseases and work-related injuries will be prevented [2].

This science is helpful in otoplasty surgery [5], forensics, biomedical engineering, and ergonomics [6]. Although several anthropometric studies are performed worldwide [2, 3, 7-11], there are few anthropometric studies in Iran. In 2015, Mehrparvar et al. studied 19 anthropometric dimensions in 9476 high school students (4703 boys and 4773 girls; age range, 15-18 years) from six ethnicities (ie, Fars, Turk, Kurd, Lor, Baluch, and Arab). The high school students significantly differed in all the anthropometric parameters, regarding gender, age, and ethnicity [12]. Dianat et al. evaluated the dimensions of the classroom furniture and nine anthropometric parameters in 978 Iranian high school students. These researchers found a considerable mismatch between the anthropometric parameters of the students and the dimensions of classroom furniture [13].

In humans, the ear is one of the facial appearance characteristics that reflect gender and age features [14]. Besides, the ear's shape and dimensions are unique just as fingerprint [15]. Thus, understanding the ear dimensions can be useful in forensics [16-18].

The ear is divided into three parts: inner, middle, and outer. The outer ear includes the pinna or auricle and the external meatus [14]. In terms of the embryology of the human ear, the pinna is devolved from six mesenchymal proliferations at the end of the first and second pharynx arches, which surround the first pharyngeal cleft called the auricular hillocks. Later, three auricular hillocks on each side of the external meatus fuse to form the definitive auricle. Any kind of malformation in the shape, size, and location of pinna can be helpful in the diagnosis of abnormalities [19].

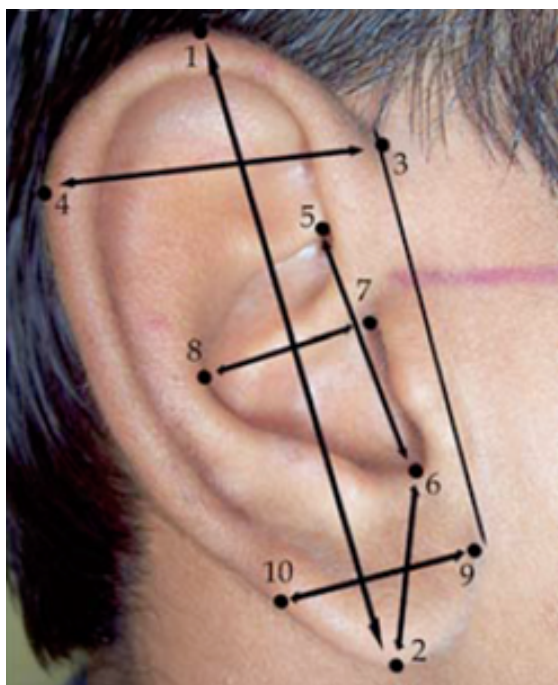
The auricle gathers the sound waves and conducts them through the tympanic membrane, so, the auricle can be considered as the primary element of acoustic modification in the auditory apparatus. The lateral surface of the auricle includes several elevations and depressions. The prominent curved rim of this surface is called the helix. The Darwin tubercle lies posterosuperior to the helix. The antihelix is another prominent curve lay anterior to the helix and is superiorly divided into two crura that surround a triangular fossa. The scaphoid fossa lies between the helix and antihelix. Indeed, the antihelix surrounds the concha. Moreover, a prominence lies anterior to the concha and inferior to helix crus and is called the tragus. The tragus is separated by antitragus and intertragic notch [20].

The congenital anomalies of the ear may occur during the developmental period of the auricle (at 5-9 weeks of gestation), maybe because of unusual pressure that affects the normal growth of the ear, during the intra-uterine life [21]. Anthropometric knowledge provides the necessary standards for the body dimensions of a region's population. Therefore, using specific indices, this study aimed to investigate the auricular form in a population from Bandar Abbas City (age range, 20-30 years). These data can help to identify congenital anomalies and would be effective in the abnormality surgeries.

2. Materials and Methods

The study participants included 400 people (200 males and 200 females) aged 20 to 30 years, in Bandar Abbas City. The subjects were recruited from the students of the Hormozgan University of Medical Sciences, the staff of teaching hospitals, the patients' visitors, and the patients admitted to different wards, except the Ear, Nose, and Throat wards. The instruments used included a vernier caliper, a goniometer, a Morrison compass, and a ruler. The auricular dimensions on both sides were compared in both sexes and the dominant type was identified to evaluate the auricular form.

We excluded the people with a history of facial cosmetic or reconstructive surgeries, a history of face or ear trauma, and head or facial deformities. Before the study, we obtained the approval of the respective authorities and explained the study objectives to the participants. Moreover, we only included subjects whose two preceding generations were residing in Bandar Abbas. The measured variables were the shape of the ear lobe, the lengths and widths of auricle and concha, cephalo-auricular angle, ear-skull distance, tragus-alar distance, nasal length, and the type of lop ear deformity. The obtained



ANATOMICAL SCIENCES

Figure 1. Auricular and Conchal Length and Width

data were analyzed with t test and Pearson correlation coefficient, in SPSS.

The auricle was measured based on the following parameters (Figure 1):

The shape of lobule (round);

The auricle length: The distance between the supraaurale and subaurale (the distance between the most superior point on auricle and the most inferior point on the earlobe) (Figure 1, from point 1 to 2) [22, 23];

The auricle width: The distance between preaurale and postaurale (Figure 1, from point 3 to 4);

The concha length: The distance between concha superior and incisura intertragica inferior (Figure 1, from point 5 to 6);

The concha width: The distance between incisura anterior auris posterior and the strongest antihelical curvature (Figure 1, from point 7 to 8) [22];

The ear-skull distance: The distance of the medial surface of the auricle to the base of mastoid at the Darwin tubercle level [23];

The cephalo-auricular angle: An angle between the medial surface of the auricle and mastoid process [24];

The nasal length: The distance between nasion and anterior nasal spine [25];

The tragus-alar distance: From the apex of tragus to the outermost adherence of nasal alar cartilage.

Also, the lop ear deformity was determined by the evaluation of 1. undeveloped antihelix; 2. the overgrowth of conchal cartilage, and 3. the protrusion of lobule [26].

3. Results

In males, the mean values of the length of the auricle, the width of the auricle, the length of the concha, the width of the concha, cephalo-auricular angle, ear-skull distance, tragus-alar distance, nasal length, and the most common lobule shape were 59.86 mm, 30.71 mm, 24.32 mm, 17.83 mm, 57.63°, 8.71 mm, 101.72 mm, 50.31 mm, and round lobule, respectively, while in females, were 60.12 mm, 31.36 mm, 25.32 mm, 17.73 mm, 55.68°, 8.40 mm, 101.36 mm, 40.76 mm, and round lobule, respectively.

Also, in the right ear, the mean values of the length of the auricle, the width of the auricle, the length of the concha, the width of the concha, cephalo-auricular angle, ear-skull distance, tragus-alar distance, and the most common lobule shape were 59.86 mm, 30.36 mm, 24.46 mm, 17.72 mm, 54.83°, 8.30 mm, 101.56 mm, and round lobule, respectively, and in the left ear, they were 60.13 mm, 31.43 mm, 25.19 mm, 17.84 mm, 58.48°, 8.81 mm, 101.52 mm, and round lobule, respectively (Tables 1 and 2).

The rates of lop ear deformity in male and female subjects were 10.5% and 7.8%, respectively. Also, the other significant differences were as follows: the auricle width between the two sexes; the auricle width in the left and right ears, regardless of gender; the width of the left and right auricles in females; the concha length between the two sexes, regardless of side; the concha length between the right and left sides, regardless of gender; the length of concha between the left and right sides, in males; the cephalo-auricular angle between the two sexes, regardless of side; the cephalo-auricular angle between the two sides, regardless of gender; the cephalo-auricular angle between the left and right sides, in males; the cephalo-auricular angle between the left and right sides, in females; the ear-skull distance between the two sexes, regardless of side; the ear-skull distance between the left and right

Table 1. Morphometric measurements of ear in a population from Bandar Abbas City (200 males and 200 females)

Measurements	Sex	Mean±SD	Side	Mean±SD
LA (mm)	Male	59.86±3.06	Left	59.99±3.08
			Right	59.74±3.04
	Female	60.12±3.37	Left	60.26±3.22
			Right	59.99±3.52
WA (mm)	Male	30.71±3.95	Left	31.05±4.14
			Right	30.37±3.74
	Female	31.36±3.64	Left	31.82±3.73
			Right	30.89±3.49
LC (mm)	Male	24.32±3.14	Left	24.86±3.04
			Right	23.77±3.15
	Female	25.32±2.54	Left	25.51±2.43
			Right	25.14±2.64
WC (mm)	Male	17.83±2.22	Left	17.75±2.30
			Right	17.90±2.15
	Female	17.73±2.12	Left	17.92±2.12
			Right	17.53±2.11
Cephalo-auricular angle (°)	Male	57.63±8.93	Left	59.45±7.76
			Right	55.80±9.63
	Female	55.68±8.62	Left	57.50±8.91
			Right	53.85±7.92
Ear-skull distance (mm)	Male	8.71±1.56	Left	8.83±1.80
			Right	8.59±1.27
	Female	8.40±1.43	Left	8.79±1.55
			Right	8.01±1.17
Tragus-alar distance (mm)	Male	101.72±4.61	Left	101.63±4.69
			Right	101.81±4.54
	Female	101.36±4.15	Left	101.41±4.40
			Right	101.31±3.90
Nasal length (mm)	Male	50.31±3.92	—	—
	Female	49.76±3.39	—	—

Table 2. Measurements of the Ear Shape and Lop Ear Deformity in a Population From Bandar Abbas City (200 Males and 200 Females)

Measurements	Sex	Shape	%	Left Side (%)	Right Side (%)
Shape of the lobule	Male	Round	67.00	67.00	67.00
		Triangular	2.00	2.00	2.00
		Flat	0.00	0.00	0.00
		Hanging	11.00	11.00	11.00
		Totally adherent	4.50	4.50	4.50
		Partially adherent	15.50	15.50	15.50
	Female	Round	66.75	63.00	70.50
		Triangular	6.75	8.50	5.00
		Flat	2.00	2.00	2.00
		Hanging	12.00	12.00	12.00
		Totally adherent	3.25	3.50	3.00
		Partially adherent	9.25	11.00	7.50
Lop ear deformity	Male	—	10.5	10.5	10.5
	Female	—	7.8	5	10.5

ANATOMICAL SCIENCES

sides, regardless of gender; the ear-skull distance on both sides, in females; and the nasal length in both sexes.

Abbreviations: LA, length of the lobule; WA, width of the lobule; LC, length of concha; WC, width of concha.

4. Discussion

Overall, 400 subjects (200 males and 200 females) with the age range of 20 to 30 years were included in this study to evaluate the shape and dimensions of auricle among the residents of Bandar Abbas. The present study mainly aimed to evaluate and compare the auricle's dimensions and shapes of the both sides and sexes and determine the dominant type. The measured variables were lobule shape, auricle and concha length and width, cephalon-auricular angle, ear-skull distance, tragus-alar distance, nasal length, and lop ear deformity.

The ear appearance is one of the facial appearance characteristics that are distinct in individuals. For many years, the reconstructive surgery of the ear has been a challenge, but tissue engineering has progressed in this regard [23]. The study of the human ear morphometry would be helpful, considering that ear dimensions differ between ethnicities and races [24]. The ear morphometry plays an important role in the recognition of congenital deformities. Any kind of deformity in auricle shape,

size, or location is contributed to the diagnosis of congenital anomalies [25], such as Down syndrome [26] and Martin-Bell syndrome [27]. Therefore, we evaluated the auricle shape and dimensions among a group of participants from Bandar Abbas to promote clinical efficiency.

Our results showed that the auricle length and width were greater in females than in males. However, the auricle length has been greater in males than in females, in an Indian population with the age range of 18-24 years [24]. Also, Kumar and Selvi studied the morphometric parameters in Malaysian and Indian people aged 20-30 years, in 2016. These authors reported that the total pinna length and width and the length of cartilaginous ear canal were greater in Malaysian males than in females, but the lobule length was greater in females; all these parameters were greater in Indian males than in Indian females [28]. In the Turkish population, males had a greater total ear length than females. Besides, the ear length significantly differs between the Turkish and Japanese populations, based on the reports of the literature [29].

in 2016, Sharma studied the northern Indian people aged 10-50 years. Results demonstrated that the total ear length and width were greater in males than in females, while the lobule length and width were greater in females than in males [30]. Besides, Sadacharan found that the ear length and width were greater in Indo-Amer-

ican males than in females (age range, 18-30 years) [5]. In a population from Urhobo, southern Nigeria, it was observed that the length of lobule was greater in females than in males, whereas the two genders did not significantly differ in other parameters, such as the ear length and width and the lobule width [31].

We observed the greater length and width of auricle on the left side, compared with the right side. This finding was similar to the results of Aktuc and Barut. They reported that the width of the left ear was longer than that of the right ear, in the high school students of Turkey, but ear length, lobule width, and the ear-face indices of the right side were nonsignificantly greater than those of the left side [9]. Also, Garba et al. reported that the total length of the right ear increased with advancing age [32].

Also, we found that the length of the left ear was nonsignificantly greater than that of the right ear, in both genders. Moreover, the concha length was significantly greater in females, while the concha width was nonsignificantly greater in males than in females. In contrast with our findings, Arora and Singh showed that the length and width of concha were greater in males than in females, but there was not any significant difference between the two sides in terms of concha width [24]. Similarly, Ahmed and Omer, as well as Zhu et al. found that the concha width was greater in males than in females [33, 34]. In our population, the concha length of the left ear in both sexes (the difference was significant in males) and the concha width of the left ear in females were nonsignificantly greater than those of the right ear. However, the concha width of the right ear was nonsignificantly greater than that of the left ear, in males.

Males had significantly a greater cephalo-auricular angle than females. It was also significantly greater on the left side than on the right side, in both sexes. The ear-skull distance (ear protrusion) was significantly more in males than in females. We measured this parameter at the level of the Darwin tubercle. Our findings were consistent with the results of Bozkir et al. and Tatlisumak et al. [29, 35]. They measured the ear protrusion at the level of the tragus. We observed that the left ear had more protrusion than the right ear, in both genders; the difference was only significant in females.

In our population, males had a longer tragus-alar distance than females. Besides, the distance was greater on the right side than on the left side, regardless of gender. Although the tragus-alar distance was greater on the left side in females and on the right side in males, these differences were not significant.

In this study, the nasal length and lop ear deformity were more in males than in females. However, only the difference in nasal length was significant. Furthermore, the round shape of lobule was more common in males, compared with females; it was completely similar on both sides, in males. However, there was an insignificant difference in females in this regard. In terms of nasal length, our findings were in line with those of Zankl et al. and Oladipo et al. [10, 36].

Finally, our study revealed considerable differences in the auricular shape and dimensions, among different ethnicities, races, genders, and age groups. Also, males had a smaller auricle size than females, but it was more symmetrical in male subjects.

Ethical Considerations

Compliance with ethical guidelines

This study was approved by the Ethics Committee of Kerman University of Medical Sciences.

Funding

This research was fully supported by Kerman University of Medical Sciences (grant No.: 89.276).

Authors' contributions

Conceptualization: Seyed Hassan Eftekhari Vaghefi; Data collection and Data analysis: Leila Elyasi; Writing – original draft: Leila Elyasi and Sanaz Araban; Writing – review & editing and Supervision: All authors.

Conflict of interest

The authors declared no conflict of interest.

Acknowledgments

We would like to thank Hormozgan University of Medical Sciences. The authors would also like to express their gratitude to all the employees who willingly participated in the data collection.

References

- [1] Pheasant S. Bodyspace anthropometry, ergonomics, and the design of work. 2nd edition. London: Taylor & Francis Ltd; 1998. https://books.google.com/books?id=1DrR_nskp8A

- [C&printsec=frontcover&source=gbs_ge_summary_r&cad=0#v=onepage&q&f=false](#)
- [2] Chuan TK, Hartono M, Kumar N. Anthropometry of the Singaporean and Indonesian populations. *International Journal of Industrial Ergonomics*. 2010; 40(6):757-66. [DOI:10.1016/j.ergon.2010.05.001]
 - [3] KIR T, Ceylan S, Hasde M. [Anthropometrine in the field of health (Turkish)]. *Turkiye Klinikleri Journal of Medical Sciences*. 2000; 20(6):378-84. <https://www.turkiyeklinikleri.com/article/tr-antropometrinin-saglik-alaninda-kullanimi-1677.html>
 - [4] Acar M, Alkan SB, Ulusoy M, Akkubak Y. Comparison of some morphometric parameters of the ear on Turkish and African students. *Asian Journal of Biomedical and Pharmaceutical Sciences*. 2017; 7(60):8-12. <https://www.alliedacademies.org/articles/comparison-of-some-morphometric-parameters-of-the-ear-on-turkish-and-african-students.html>
 - [5] Sadacharan CM. Ear morphometry on Indian Americans and its clinical importance. *International Journal of Applied Research*. 2016; 2(1):348-53. [DOI:10.15406/mojap.2015.01.00020]
 - [6] Eftekhar Vaghefi SH, Elyasi L, Amirian SR, Raigan P, Akbari H, Sheikhshoaeie M, et al. Evaluating anthropometric dimensions of the femur using direct and indirect methods. *Anatomical Sciences Journal*. 2015; 12(2):89-92. <http://anatomyjournal.ir/article-1-107-en.html>
 - [7] Asher MA, Strippgen WE. Anthropometric studies of the human sacrum relating to dorsal transsacral implant designs. *Clinical Orthopaedics and Related Research*. 1986; (203):58-62 [DOI:10.1097/00003086-198602000-00008] [PMID]
 - [8] DeLude JA, Bicknell RT, MacKenzie GA, Ferreira LM, Dunning CE, King GJW, et al. An anthropometric study of the bilateral anatomy of the humerus. *Journal of Shoulder and Elbow Surgery*. 2007; 16(4):477-83. [DOI:10.1016/j.jse.2006.09.016] [PMID]
 - [9] Barut C, Aktunc E. Anthropometric measurements of the external ear in a group of Turkish primary school students. *Aesthetic Plastic Surgery*. 2006; 30(2):255-9. [DOI:10.1007/s00266-005-0182-1] [PMID]
 - [10] Oladipo GS, Eroje MA, Fahwehinmi HB. Anthropometric comparison of nasal indices between Andoni and Okrika tribes of Rivers State, Nigeria. *International Journal of Medicine and Medical Sciences*. 2009; 1(4):135-7. <https://doi.org/10.5897/IJMMS.9000019>
 - [11] Lin Y-C, Wang M-JJ, Wang EM. The comparisons of anthropometric characteristics among four peoples in East Asia. *Applied Ergonomics*. 2004; 35(2):173-8. [DOI:10.1016/j.apergo.2004.01.004] [PMID]
 - [12] Mehrparvar AH, Mirmohammadi SJ, Hafezi R, Mostaghaci M, Davari MH. Static anthropometric dimensions in a population of Iranian high school students: Considering ethnic differences. *Human Factors*. 2015; 57(3):447-60 [DOI:10.1177/0018220814549579] [PMID]
 - [13] Dianat I, Karimi MA, Hashemi AA, Bahrapour S. Classroom furniture and anthropometric characteristics of Iranian high school students: Proposed dimensions based on anthropometric data. *Applied Ergonomics*. 2013; 44(1):101-8. [DOI:10.1016/j.apergo.2012.05.004] [PMID]
 - [14] Standring S. *Gray's Anatomy*. 40th edition. Amsterdam: Elsevier; 2008.
 - [15] Murgod V, Angadi P, Hallikerimath S, Kale A. Anthropometric study of the external ear and its applicability in sex identification: Assessed in an Indian sample. *Australian Journal of Forensic Sciences*. 2013; 45(4):431-44. [DOI:10.1080/00450618.2013.767374]
 - [16] Purkait R, Singh P. Anthropometry of the normal human auricle: A study of adult Indian men. *Aesthetic Plastic Surgery*. 2007; 31(4):372-9. [DOI:10.1007/s00266-006-0231-4] [PMID]
 - [17] Kumar P, Singla A. Ear biometric: Sex, bilateral and ethnic differences among brahmin and yadav communities of Bundelkhand region using PCA technique. *International Journal of Scientific & Engineering Research*. 2013; 4(10):799-805. <https://www.ijser.org/researchpaper/Ear-Biometric-Sex-Bilateral-and-Ethnic-Differences-Among-Brahmin-and-Yadav-Communities.pdf>
 - [18] Meijerman L, Sholl S, De Conti F, Giacomini M, van der Lugt C, Drusini A, et al. Exploratory study on classification and individualisation of earprints. *Forensic Science International*. 2004; 140(1):91-9. [DOI:10.1016/j.forsciint.2003.10.024] [PMID]
 - [19] Sadler TW. *Langman's medical embryology*. 12th edition. Philadelphia: Lippincott Williams & Wilkins; 2011.
 - [20] Standring S. *Gray's anatomy*. 41th edition. Amsterdam: Elsevier; 2015.
 - [21] Tan ST, Abramson DL, MacDonald DM, Mulliken JB. Molding therapy for infants with deformational auricular anomalies. *Annals of Plastic Surgery*. 1997; 38(3):263-8. [DOI:10.1097/0000637-199703000-00013] [PMID]
 - [22] Knussmann R. *Anthropologie. Band I: Wesen und Methoden der Anthropologie*. Gustav; 1988.
 - [23] Staudenmaier R, Hoang NT, Mandlik V, Schurr C, Burghartz M, Hauber K, et al. Customized tissue engineering for ear reconstruction. *Aesthetics and Functionality in Ear Reconstruction*. 2010; 68:120-31. [DOI:10.1159/000314567] [PMID]
 - [24] Arora L, Singh V. Morphometric study of human auricle in the age group of 18-24 years in North West part of India. *Global Journal of Medicine and Health*. 2016; 5(6):1-6.
 - [25] Sadler TW. *Longman medical embryology*. 8th edition. Philadelphia: Lippincott Williams and Wilkins; 2000. https://books.google.com/books?id=ODBLQc2BdDIC&source=gbs_citations_module_r&cad=7
 - [26] Allanson J, O'Hara P, Farkas LG, Nair RC. Anthropometric craniofacial pattern profiles in Down syndrome. *American Journal of Medical Genetics*. 1993; 47(5):748-52. [DOI:10.1002/ajmg.1320470530] [PMID]
 - [27] Loesch DZ, Lafranchi M, Scott D. Anthropometry in Martin-Bell syndrome. *American Journal of Medical Genetics*. 1988; 30(1-2):149-64. [DOI:10.1002/ajmg.1320300113] [PMID]
 - [28] Kumar BS, Selvi GP. Morphometry of ear pinna in sex determination. *International Journal of Anatomy and Research*. 2016; 4(2):2480-84. [DOI:10.16965/ijar.2016.244]
 - [29] Bozkır MG, Karakaş P, Yavuz M, Dere F. Morphometry of the external ear in our adult population. *Aesthetic Plastic Surgery*. 2006; 30(1):81-5. [DOI:10.1007/s00266-005-6095-1] [PMID]

- [30] Sharma N. Anthropometric measurement and cross-sectional surveying of ear pinna characteristics in Northern India. *Journal of Experimental and Clinical Anatomy*. 2016; 15(2):102-6. [DOI:10.4103/1596-2393.200914]
- [31] Eboh DEO. Morphological changes of the human pinna in relation to age and gender of Urhobo people in Southern Nigeria. *Journal of Experimental and Clinical Anatomy*. 2013; 12(2):68-74. [DOI:10.4103/1596-2393.127964]
- [32] Ekanem A, Garba SH, Musa TS, Dare ND. Anthropometric study of the pinna (Auricle) among adult Nigerians resident in Maiduguri metropolis. *Journal of Medical Sciences*. 2010; 10(6):176-80. [DOI:10.3923/jms.2010.176.180]
- [33] Ahmed AA, Omer N. Estimation of sex from the anthropometric ear measurements of a Sudanese population. *Legal Medicine*. 2015; 17(5):313-9. [DOI:10.1016/j.legalmed.2015.03.002] [PMID]
- [34] Zhu Z, Ji X, Gao Z, Hu G. A morphometric study of auricular concha in the population of young Chinese adults. *International Journal of Morphology*. 2017; 35(4):1451-8. [DOI:10.4067/S0717-95022017000401451]
- [35] Tatlisumak E, Yavuz MS, Kutlu N, Asirdizer M, Yoleri L, Aslan A. Asymmetry, handedness and auricle morphometry. *International Journal of Morphology*. 2015; 33(4):1542-8. [DOI:10.4067/S0717-95022015000400057]
- [36] Zankl A, Eberle L, Molinari L, Schinzel A. Growth charts for nose length, nasal protrusion, and philtrum length from birth to 97 years. *American Journal of Medical Genetics*. 2002; 111(4):388-91. [DOI:10.1002/ajmg.10472] [PMID]