

# Review Paper: A Rare Variation in Origin of Common Interosseous Artery: A Review of Anatomical Studies and Case Report

Saieed Babae<sup>1</sup>, Maryam Baazm<sup>1</sup>, Parvindokht Bayat<sup>1</sup>, Mohammad Bayat<sup>1</sup>, Mohammad Hassan Sakhaie<sup>1\*</sup>

1. Department of Anatomy, School of Medicine, Arak University of Medical Sciences, Arak, Iran.

**Citation:** Babae S, Baazm M, Bayat P, Bayat M, Sakhaie MH. A Rare Variation in Origin of Common Interosseous Artery: A Review of Anatomical Studies and Case Report. *Anatomical Sciences*. 2016; 13(4):203-206.



Dr. Mohammad Hasan Sakhaie is the assistance professor of Anatomical Sciences, at the Department of Anatomy, School of Medicine, Arak University of Medical Sciences. His research interests are Neurodegenerative disease, Neurosciences, and Gross anatomy.

## Article info:

Received: 21 May 2016

Accepted: 01 Sep. 2016

## Keywords:

Anatomic variation,  
Interosseous artery, Radial  
artery, Ulnar artery

## ABSTRACT

An unusual origin of the common interosseous artery is reported in the paper. During educational dissection of a 37-year-old male, a rare variation in the origin of common interosseous artery of the right upper limb was observed. The common interosseous artery directly separated from radial artery. The right anterior interosseous artery is continued from common interosseous artery. Anterior and posterior ulnar recurrent arteries arising from common interosseous artery were noted on the right side of upper limb. In the present case, the median artery was replaced with anterior interosseous artery. Additionally, the ulnar artery passed superficially on flexor digitorum superficialis. In the cadaver, there was no other arterial or muscular variation. The embryological interpretation of this variation may be attributed to arising of the artery as a result of modifications to the normal pattern of capillary vessel maintenance and regression. Regarding the above mentioned variations, practical medical experiences are necessary to identify the variations of arterial pattern of upper limb vessels.

## 1. Introduction

# A

natomists and surgeons noticed the variations of origin and course of the principal arteries in the upper extremities. The prevalence of unusual path of arteries in upper

limb were reported around 18% [1]. Normally, the ulnar artery is the greater terminal branches of brachial artery. It starts at the cubital fossa against radial tuberosity and leaves the fossa by passing deep to heads of the pronator teres muscle. It runs along the medial border of the forearm and lateral side of the ulnar nerve and enters

### \* Corresponding Author:

Mohammad Hassan Sakhaie, PhD

Address: Department of Anatomy, School of Medicine, Arak University of Medical Sciences, Arak, Iran.

Tel: +98 (86) 34173505

E-mail: mh.sakhaie@arakmu.ac.ir

the palm by passing superficial to the flexor retinaculum. Normally, common interosseous artery is a short branch of the proximal part of ulnar artery [2, 3]. It descends on interosseous membrane, dividing to anterior and posterior interosseous arteries. These branches supply anterior and posterior aspects of forearm. The other branches of ulnar artery, anterior and posterior ulnar recurrent, contributes to anastomotic network of vessels around the elbow joint [4].

## 2. Case Report

During educational dissection of a 37-year-old male cadaver, some variations in the right upper limb, including the origin of the common interosseous artery (Figure 1), superficial route of ulnar artery, and anterior and posterior ulnar recurrent were observed (Figure 2).

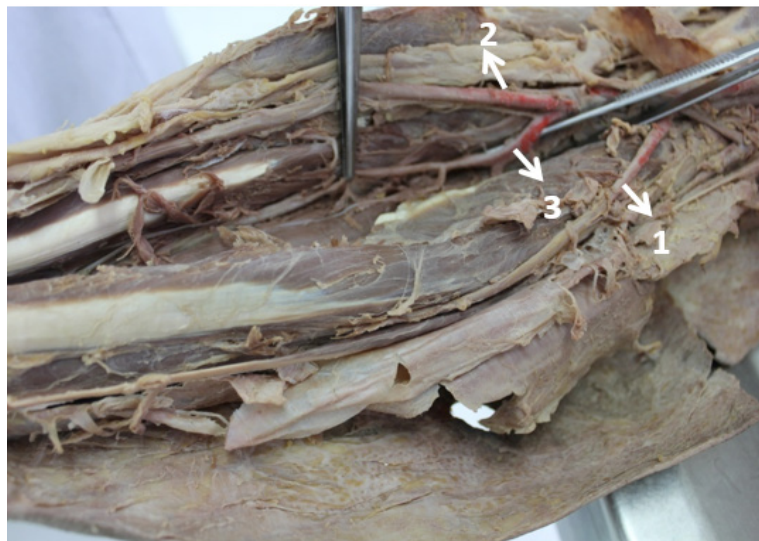
In the present case also the caliber of radial artery was larger than that of ulnar artery. On the left side, there was not any variation in route of arteries. The short trunk of the common interosseous artery directly separated from radial artery 5.5 cm below the elbow joint. Immediately it divided into the anterior and posterior interosseous arteries. Posterior interosseous artery passed backward through interosseous membrane to posterior aspect of forearm. The anterior interosseous artery descended deeply on interosseous membrane, overlapped by contiguous sides of flexor digitorum profundus and flexor pollicis longus and supplied deep anatomical elements. Ulnar artery had superficial course and traversed on pronator teres and flexor digitorum superficialis muscles under the cover of skin and superficial fascia (Figure

1). The course of an ulnar artery over the forearm flexor muscles was previously reported by Natsis et al [5]. The ulnar artery finally passed down over the front of the wrist in to the palm.

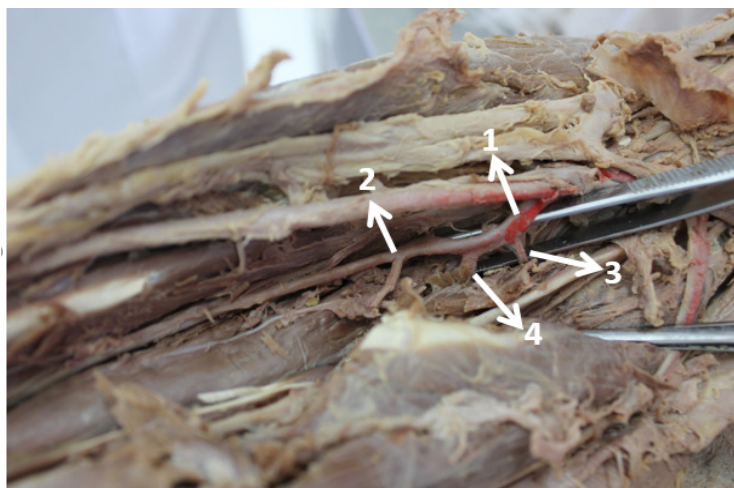
## 3. Discussion

Variations in the pattern of upper limb arteries explored mostly during anatomical dissection, angiographic studies, or incidentally during surgery, are a potential source of pitfalls and difficulties in medical practices. However, the knowledge does not clearly explain how or when these variations arise during the development. The prevalence of variation in upper extremity vessels is about 9% to 18.5% [1, 6]. These variations can be explained as failure in normal embryologic development of the upper limb vascular plexus [7]. Rodriguez et al. believed that the pattern of variations arise through the persistence, enlargement, and differentiation of parts of the initial network, which would normally remain as capillaries or even regression [8].

Several reports described the variations in the arterial plexus of the upper limb and hand [1, 6, 9]. Bilodi et al. reported the variation in right upper limb, the brachial artery terminated into ulnar and radial arteries [10], and the common interosseous arteries arising from the radial artery, but not from ulnar artery [11]. Similar cases were reported in other literature [12, 13]. The axial artery in the developing limb bud includes both subclavian and axillary arteries. The origin of anomalies in the branching pattern of the upper limb buds is attributed to the defects



**Figure 1.** The volar aspect of dissected elbow and forearm region  
1: Ulnar artery; 2: Radial artery; 3: Common interosseous artery



**Figure 2.** Right forearm arterial variation in origin of common interosseous artery and branches

ANATOMICAL SCIENCES

1: Common interosseous artery; 2: Anterior interosseous artery; 3: Anterior ulnar recurrent artery; 4: Post interosseous artery

in the embryonic development (sprouting and regression) of vascular plexus [14].

Development of vasculature pattern of upper limb takes place by a complex process. Some studies suggest that arterial pattern development in the forearm occurs following the initial capillary plexus with an anterior-posterior polarity due growth, enlargement, and differentiation of certain capillary vessels, and the regression of others [8]. In the current study, a common interosseous artery was observed as one of the main proximal branches of radial artery (Figure 1). The pattern suggested in the present study may be related to regression through origin of radial artery to lower place than that of normal position raised by Singer in the stage 5 of developmental pattern of arterial plexus in upper limb [15].

In agreement with the results of the current study, some studies reported the origin of common interosseous artery from radial artery [14, 16]. It may also originate from axillary or brachial artery. Previous studies showed the high origin of radial and common interosseous arteries [17]. A superficial course of ulnar artery under the antebrachial fascia was observed in the current case report. The incidence rate of superficial ulnar artery was reported in 2% of the cases [18]. Mehta et al. reported a case of an anomaly in the ulnar artery. It traversed superficially on the muscles of ulnar side of forearm and continued to be in the same plane in the forearm as well [11]. The presence of a superficial ulnar artery may be due to developmental arrest of arterial network, limb development, and genetic factors also may be related to the predominance of hemodynamic factors at the origin of the ulnar artery [19-21].

Another variation in the current study was the origin of anterior and posterior ulnar recurrent arteries that originated separately from common interosseous artery. Similar to the results of the current study, Babu reported the origin of anterior and posterior ulnar recurrent by a common trunk from common interosseous artery [14]. In a study on the incidence of superficial route of upper limb arteries, D'Costa et al. reported the origin of anterior and posterior ulnar recurrent originated from common interosseous artery [22]. The mechanisms of change in route of this arterial variation are unknown. It may be due to alteration in origin, differentiation, and the hemodynamics of vascular plexus.

#### 4. Conclusion

The study suggested that giving off the common interosseous artery from radial artery in upper limb occurred during the first stage of embryological patterns of upper limb arterial system. The proximal attachment of radial artery was regressed in the 5 stage, but the origin of this artery takes place below the classic place. Finally, the study suggests physicians to consider routine imaging examinations for patients before performing any surgical procedures.

#### Acknowledgements

The current research did not receive any financial support. Authors wish to thank Mr. Shakeri for cooperation with the study.

#### Conflict of Interest

Authors declared no conflicts of interest.

## References

- [1] Ciervo A, Kahn M, Pangilinan AJ, Dardik H. Absence of the brachial artery: Report of a rare human variation and review of upper extremity arterial anomalies. *Journal of Vascular Surgery*. 2001; 33(1):191-4. doi: 10.1067/mva.2001.112212
- [2] Standing S, Ellis H, Healy J, Johnson D, Williams A, Collins P, et al. Gray's anatomy: The anatomical basis of clinical practice. *American Journal of Neuroradiology*. 2005; 26(10):2703.
- [3] Drake R, Vogl AW, Mitchell A. *Grays anatomy for students*. London: Churchill Livingstone; 2009.
- [4] Snell RS. *Clinical anatomy by regions*. Philadelphia: Lippincott Williams & Wilkins; 2011.
- [5] Natsis K, Papadopoulou AL, Paraskevas G, Totlis T, Tsikarakas P. High origin of a superficial ulnar artery arising from the axillary artery: Anatomy, embryology, clinical significance and a review of the literature. *Folia Morphologica*. 2006; 65(4):400-5.
- [6] McComarck LJ, Cauldwell EW, Anson J. Brachial and antebrachial arterial patterns. *Surgery, Gynecology & Obstetrics*. 1953; 96(1):43-54. PMID: 13015348
- [7] Jurjus AR, Correa De Aruaujo R, Bohn RC. Bilateral double axillary artery: Embryological basis and clinical implications. *Clinical Anatomy*. 1999; 12(2):135-40. doi: 10.1002/(sici)1098-2353(1999)12:2<135::aid-ca10>3.0.co;2-m
- [8] Rodríguez Niedenfür M, Burton GJ, Deu J, Sañudo JR. Development of the arterial pattern in the upper limb of staged human embryos: Normal development and anatomic variations. *The Journal of Anatomy*. 2001; 199(4):407-17. doi: 10.1046/j.1469-7580.2001.19940407.x
- [9] Celik HH, Görmüs G, Aldur MM, Ozcelik M. Origin of the radial and ulnar arteries: variations in 81 arteriograms. *Morphologie*. 2001; 85(269):25-7. PMID: 11534414
- [10] Bilodi AK, Sanikop MB. Variations in termination of brachial artery—a case report. *Kathmandu University Medical Journal (KUMJ)*. 2004;2(1):49-51. PMID:19780289
- [11] Mehta V, Arora J, Suri RK, Rath G. Unilateral anomalous arterial pattern of human upper limb: Anatomical description and clinical implications. *Sultan Qaboos University Medical Journal*. 2008; 8(2):227-30. PMCID: PMC3074820
- [12] Jacob J, Deshpande R, Desai J. Superficial ulnar artery. *European Journal of Cardio-Thoracic Surgery*. 2005; 28(3):494. doi: 10.1016/j.ejcts.2005.02.048
- [13] Yazar F, Kirici Y, Ozan H, Aldur MM. An unusual variation of the superficial ulnar artery. *Surgical and Radiologic Anatomy*. 1999; 21(2):155-7. doi: 10.1007/s00276-999-0155-1
- [14] Babu BP. Anomalous origin of common interosseous, anterior and posterior ulnar recurrents by a common trunk from radial artery: A case report. *Anatomica Karnataka*. 2011; 5(1):72-5.
- [15] Singer E. Embryological pattern persisting in the arteries of the arm. *The Anatomical Record*. 1933; 55(4):403-9. doi: 10.1002/ar.1090550407
- [16] Acarturk TO, Tuncer U, Aydoğan LB, Dalay AC. Median artery arising from the radial artery: Its significance during harvest of a radial forearm free flap. *Journal of Plastic, Reconstructive & Aesthetic Surgery*. 2008; 61(10):e5-8. doi: 10.1016/j.bjps.2007.10.026
- [17] Cherian SB. Superficial course of brachial and ulnar arteries and high origin of common interosseous artery. *International Journal of Anatomical Variations*. 2009; 2(1):4-6.
- [18] Natsis K, Papadopoulou AL, Paraskevas G, Totlis T, Tsikarakas P. High origin of a superficial ulnar artery arising from the axillary artery: Anatomy, embryology, clinical significance and a review of the literature. *Folia Morphologica*. 2006; 65(4):400-5.
- [19] Poteat WL. Report of a rare human variation: Absence of the radial artery. *The Anatomical Record*. 1986; 214(1):89-95. doi: 10.1002/ar.1092140115
- [20] Aharinejad S, Nourani F, Hollensteiner H. Rare case of high origin of the ulnar artery from the brachial artery. *Clinical Anatomy*. 1997; 10(4):253-8. doi: 10.1002/(sici)1098-2353(1997)10:4<253::aid-ca7>3.0.co;2-t
- [21] Jacquemin G, Lemaire V, Medot M, Fissette J. Bilateral case of superficial ulnar artery originating from axillary artery. *Surgical and Radiologic Anatomy*. 2001; 23(2):139-43. doi: 10.1007/s00276-001-0139-2
- [22] D'Costa S, Shenoy BM, Narayana K. The incidence of a superficial arterial pattern in the human upper extremities. *Folia Morphologica*. 2004; 63(4):459-63.