

## Short Communication: Anatomical Variations of Vertebral Artery

Ebrahim Momeni\*, Ebrahim Esfandiari<sup>1</sup>

*1. Department of Anatomical Sciences and Molecular Biology, School of Medicine, Isfahan University of Medical Sciences, Isfahan, Iran.*

**Citation:** Momeni E, Esfandiari E. Anatomical variations of vertebral artery: Short communication. *Anatomical Sciences*. 2016; 13(1):61-62.



Ebrahim Momeni Graduated from MSc Anatomy, Department of Anatomical Sciences and Molecular Biology, School of Medicine, Isfahan University of Medical Sciences, Isfahan, Iran. His research interests are studying toxic effects of antineoplastic drugs. He is also interested in comparative anatomy and embryology.

Article info:

Received: 21 Aug. 2015

Accepted: 11 Dec. 2015

### Key Words:

Vertebral arteries, Subclavian arteries, Variation

### ABSTRACT

**Introduction:** Vertebral arteries arise from the root of the neck as the first branches from the superior-posterior aspect of the subclavian arteries. They ascend the neck to enter the cranial cavity and supply blood to the brain.

**Methods:** A total of 20 cadavers (in 10 years) were dissected for the study of variations in the origin of the vertebral artery. This study was conducted in Isfahan University of Medical Sciences.

**Results:** In 19 cadavers, left vertebral artery originated from the first part of the subclavian artery. But, in one cadaver, left vertebral artery originated from the aortic arch between the left common carotid and subclavian artery.

**Conclusion:** The anatomic and morphologic variations of the vertebral artery are significant for diagnostic and surgical procedures in the head and neck region.

### 1. Introduction

**V**ertebral arteries originate from the root of the neck as the first branches from the superior-posterior aspect of the subclavian arteries [1]. Then, vertebral arteries ascend the neck to enter the cranial cavity and supply blood to the brain. The 2 vertebral arteries are usually unequal in

size; the left one is usually larger than the right one [2]. This information is important for endovascular or cardiothoracic operations in the head and neck region. This has become more important in the era of carotid artery stents, vertebral artery stents, and new therapeutic options for intracranial interventions [3].

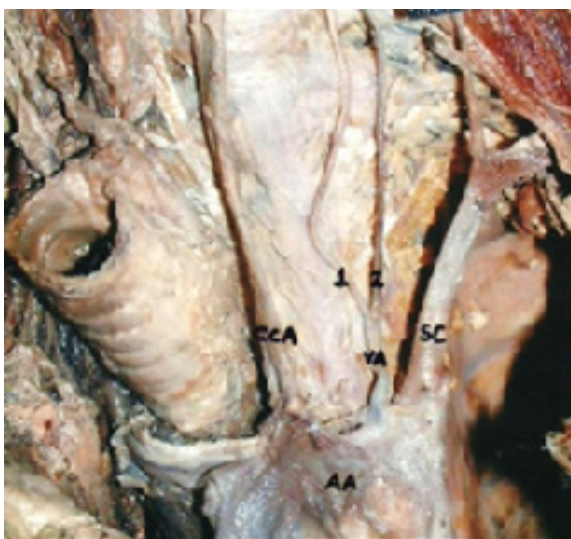
#### \* Corresponding Author:

*Ebrahim Momeni, MSc.*

*Address: Department of Anatomical Sciences and Molecular Biology, School of Medicine, Isfahan University of Medical Sciences, Isfahan, Iran.*

*Tel: +98 (913) 8058559*

*E-mail: ebrahimmomeni136@gmail.com*



ANATOMICAL SCIENCES

**Figure 1.** Left vertebral artery (VA) originating from aortic arch (AA) between left common carotid artery (CCA) and left subclavian artery (SC), bifurcating into 2 branches (1 and 2).

## 2. Materials and Methods

A total of 20 cadavers (in 10 years) were dissected for the study of variations in the origin of the vertebral artery. This study was conducted in Isfahan University of Medical Sciences. Deep dissection was done in the head and neck region to expose the vertebral arteries in the scaleno-vertebral triangle on both the right and the left sides. Thus, a total of 40 vertebral arteries were exposed.

## 3. Results

In 20 cadavers, right vertebral arteries originated in the root of the neck as the first branches from the subclavian arteries. In 19 cadavers, left vertebral artery originated from the first part of the subclavian artery. While in one cadaver, left vertebral artery originated from the aortic arch between the left common carotid and subclavian artery and then was divided in 2 branches (Figure 1).

## 4. Discussion

The anatomic and morphologic variations of the vertebral artery are significant for diagnostic and surgical procedures in the head and neck region. It is of clinical importance to know the origin, course, and variations of prevertebral segment of the vertebral artery in detail to prevent surgical complications.

## Acknowledgements

The current research hasn't received any financial support.

## Conflict of Interests

The authors declared no conflict of interests.

## References

- [1] Poonam Singla RK, Sharma T. Incident of anomalous origins of vertebral artery. *Journal of Clinical and Diagnostic Research*. 2010; 4(3):2626-631.
- [2] Poonam Singla RK, Sharma T, Sachdeva K. Variant origin of left vertebral artery. *International Journal of Anatomical Variations*. 2010; (3):97-99.
- [3] Vikram N, Patil MB, Basavaraj B, Badiger YD. Anatomical variation of the origin of the left vertebral artery: a case report. *International Journal of Current Research & Review*. 2013; 5(11):133-36.