

Case Report: An Uncommon Variation of the Superior Laryngeal Artery

Samereh Dehghani-Soltani¹, Seyed Hassan Eftekhari-Vaghefi¹, Abdolreza Babaei^{1*}

1. Department of Anatomical Sciences, School of Medicine, Kerman University of Medical Sciences, Kerman, Iran.

Citation: Dehghani-Soltani S, Eftekhari-Vaghefi SH, Babaei AR. Case report: An uncommon variation of the superior laryngeal artery. *Anatomical Sciences*. 2016; 13(1):63-66.



Abdolreza Babaei is the PhD student in Department of Anatomical Sciences at Kerman University of Medical Sciences, Kerman, Iran. He has obtained his Master's degree in Anatomical Sciences from Kerman University of Medical Sciences, Kerman, Iran. His Master's thesis was about neuronal injury and astrogliosis.

Article info:

Received: 17 Aug. 2015

Accepted: 10 Nov. 2015

Key Words:

Superior laryngeal artery,
Thyroid foramen, Arterial
variation

ABSTRACT

This case study reports a rare variation of the superior laryngeal artery (SLA), which is the principal arterial supply of the larynx. The knowledge of the arterial variations is essential for the surgeons to prevent blood loss and postoperative complications. During routine dissection of an adult male cadaver, a rare arterial variation in the SLA was seen. In this case, the SLA passed through the thyroid foramen. The present study provides significant information about the SLA. We hope that it helps describe the arterial bleeding that may happen during laryngeal surgery.

1. Introduction

The superior laryngeal artery (SLA) is one of the branches of the superior thyroid artery. SLA is normally accompanies the internal branch of the superior laryngeal nerve, deep to the thyrohyoid muscle, and pierces the thyrohyoid membrane [1, 2]. It is the principal arterial supply of the upper larynx mucosa and laryngeal muscles. SLA also anastomoses with the ipsilateral inferior

laryngeal artery and with the branch from the opposite side of the neck [3, 4].

Variations in the branching pattern of the arterial system in the neck region, especially arteries that accompany neural branches, are important in many surgical procedures such as microsurgical revascularization of the larynx, partial laryngectomy, and carotid endarterectomy. In all mentioned operations, the SLA plays a significant role [5-7]. Variations in the SLA origins is rare.

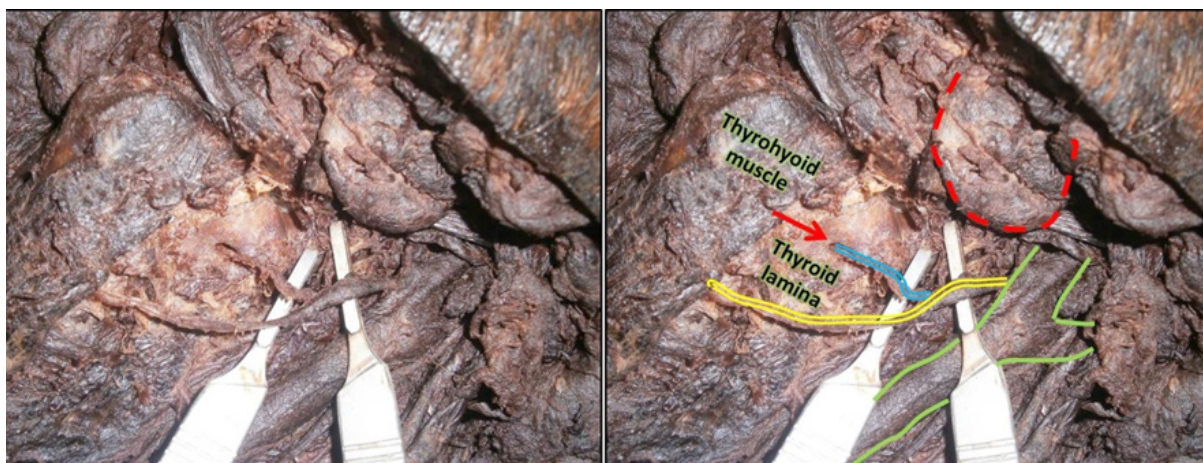
* Corresponding Author:

Abdolreza Babaei, PhD Candidate

Address: Department of Anatomical Sciences, School of Medicine, Kerman University of Medical Sciences, Kerman, Iran.

Tel: +98 (917) 7091063

E-mail: babaei.ab@gmail.com



ANATOMICAL SCIENCES

Figure 1. Photographs showing anterolateral view of the dissected neck with thyroid foramen (arrow), SLA (blue), superior thyroid artery (yellow), common carotid artery and its bifurcation (green), and submandibular gland (red) in a male cadaver.

The previous studies have demonstrated that SLA may arise from the external carotid, ascending pharyngeal, facial or lingual arteries [8-10]. However, there are few studies related to the variation of entrance of SLA into larynx. The knowledge of the arterial variations of the SLA is essential for the surgeons to prevent blood loss and reduce postoperative complications [11, 12]. Thus, in the present study, we describe a neck region arterial variation in which SLA passes through the thyroid cartilage.

2. Case Report

The human cadaver was in the dissection room, Department of Anatomy, Kerman University of medical science, Iran. During a regular dissection procedure at the dissection hall on a cadaver (male, 40-50 year old), an arterial variation in the neck region was detected. In this case, the SLA passed through the thyroid foramen (Figure 1). It was situated at the superior part of the thyroid lamina and 0.5 cm posterior to the oblique line (with 3 mm diameter).

3. Discussion

The thyroid foramen has been described by Segond, Gruber, Lang et al. and Grosser as being uncommon in occurrence [8, 13-15]. Understanding the accurate surgical anatomy of the SLA and its relationship with other structures is very important in microsurgery procedures of larynx and anterior region of neck [16]. If SLA cannot be found during surgical operation, a variation must be considered. Leon et al. and Tanaka et al. reported that thyroid foramen provides the way for a branch of the external branch of the superior laryngeal nerve [17, 18], but in the present study we observed that the SLA passed through this foramen. According to previous studies,

its diameter varies from 1 to 8 mm [14, 19, 20]. In this study the diameter of thyroid foramen was 3 mm. From the perspective of embryology, 2 hypotheses have been proposed to elucidate the origin of the thyroid foramen. The first is the neurovascular theory that is associated with defect of chondrogenesis in the thyroid lamina originated by the presence of the nerves and or vessels [21, 22]. The second is the branchial origin, i.e., thyroid foramen is considered as an imperfect union of the cartilaginous part of the sixth and fourth pharyngeal arches from which the lamina of thyroid cartilage is derived [14, 23, 24]. On the whole, the knowledge of the arterial variations is very important. Furthermore, during surgical operation cautious dissection in the anterior region of the neck and close to the superior pole of the thyroid gland are essential to avoid SLA injury and bleeding.

Acknowledgements

The current research hasn't received any financial support.

Conflict of Interests

The authors of this study declared no conflict of interests.

References

- [1] Anagnostopoulou S, Mavridis I. Emerging patterns of the human superior thyroid artery and review of its clinical anatomy. *Surgical and Radiologic Anatomy*. 2014; 36(1):33-38.
- [2] Terayama N, Sanada J, Matsui O, Kobayashi S, Kawashima H, Yamashiro M, et al. Feeding artery of laryngeal and hy-

- popharyngeal cancers: role of the superior thyroid artery in superselective intraarterial chemotherapy. *Cardiovascular and Interventional Radiology*. 2006; 29(4):536-43.
- [3] Lu WT, Sun SQ, Huang J, Zhong Y, Xu J, Gan SW, et al. An applied anatomical study on the external laryngeal nerve loop and the superior thyroid artery in the neck surgical region. *Anatomical Science International*. 2015; 90(4):209-15.
- [4] Nayak SR, Krishnamurthy A, Prabhu LV, Potu BK, Bagoji IB, Jiji PJ, et al. Variable origin of the superior laryngeal artery and its clinical significance. *Al Ameen Journal of Medical Science*. 2011; 4(1):69-74.
- [5] Ozgur Z, Govsa F, Celik S, Ozgur T. Clinically relevant variations of the superior thyroid artery: an anatomic guide for surgical neck dissection. *Surgical and Radiologic Anatomy*. 2009; 31(3):151-59.
- [6] Patel JP, Dave RV, Shah RK, Kanani SD, Nirvan AB. A study of superior thyroid artery in 50 cadavers. *International Journal of Biological Medicine Research*. 2013; 4:2875-878.
- [7] Rusu MC, Nimigean V, Banu MA, Cergan R, Niculescu V. The morphology and topography of the superior laryngeal artery. *Surgical and Radiologic Anatomy*. 2007; 29(8):653-60.
- [8] Lang J, Nachbaur S, Fischer K, Vogel E. The superior laryngeal nerve and the superior laryngeal artery. *Acta Anatomica*. 1986; 130(4):309-18.
- [9] Markogiannakis H, Zografos GC, Manouras A. Prevention of superior laryngeal nerve injury in thyroid surgery. *Hellenic Journal of Surgery*. 2015; 87(1):85-88.
- [10] Nayak BS, Soumya KV. Neurovascular variations in the carotid triangle. *International Journal of Anatomical Variations*. 2008; 1:17-18.
- [11] Dziegielewski PT, Ho ML, Rieger J, Singh P, Langille M, Harris JR, et al. Total glossectomy with laryngeal preservation and free flap reconstruction: Objective functional outcomes and systematic review of the literature. *Laryngoscope*. 2013; 123(1):140-45.
- [12] Shaha AR. Revision thyroid surgery-technical considerations. *Otolaryngologic Clinics of North America*. 2008; 41(6):1169-183.
- [13] Grosser O. Der nerv des funften visceralbogens beim menschen. *Anatomischer Anzeiger*. 1910; 37:333-36.
- [14] Ortug C, Gunduz T, Sam B. The incidence of the foramen thyroideum in Turkish population. *Surgical and Radiologic Anatomy*. 2005; 27(6):491-94.
- [15] Segond LA. Mémoire sur l'ossification des cartilages du larynx. Rignoux, Paris: Imprimeur de la Faculté de Médecine, Rue Monsieur-le-Princ; 1847.
- [16] Liu JL, Liang CY, Xiang T, Wang F, Wang LH, Liu SX, et al. Aberrant branch of the superior laryngeal artery passing through the thyroid foramen. *Clinical Anatomy*. 2007; 20(3):256-59.
- [17] León X, Marañillo E, Mirapeix RM, Quer M, Sañudo JR. Foramen thyroideum: a comparative study in embryos, fetuses, and adults. *Laryngoscope*. 1997; 107(8):1146-150.
- [18] Tanaka S, Shoumura S, Chen H, Nakatani T, Mizukami S. Aberrant branch of the superior laryngeal nerve passing through the thyroid foramen: a macroscopical study. *Kaibogaku zasshi. Journal of Anatomy*. 1997; 72(4):251-56.
- [19] Roncallo P. Researches about ossification and conformation of the thyroid cartilage in men. *Acta Oto-Laryngologica*. 1948; 36(2):110-34.
- [20] Rassekh CH, Driscoll BP, Seikaly H, Laccourreye O, Calhoun KH, Weinstein GS. Preservation of the superior laryngeal nerve in supraglottic and supracricoid partial laryngectomy. *Laryngoscope*. 1998; 108(3):445-47.
- [21] Ramsaroop L, Hurrinarain K, Partab P, Satyapal KS. The Incidence of the Foramen Thyroideum in the South African Population. *International Journal of Morphology*. 2010; 28(2):433-38.
- [22] Raikos A, Paraskevas GK. The thyroid foramen. *Clinical Anatomy*. 2013; 26(6):700-08.
- [23] Zemlin WR, Simmon A, Hammel D. The frequency of occurrence of foramen thyroideum in the human larynx. *Folia Phoniatica et Logopaedica*. 1984; 36(6):296-300.
- [24] Cicekcibasi AE, Keles B, Uyar M. The morphometric development of the fetal larynx during the fetal period. *International Journal of Pediatric Otorhinolaryngology*. 2008; 72(5):683-91

