

Case Report: Unilateral Incompletely Duplicated Ureter without any Accessory Renal Artery

Fateme Tahmasebi ¹, Shirin Barati ¹, Zohreh Mazaheri ^{1*}

1. Department of Anatomical Sciences, Faculty of Medicine, Tarbiat Modares University, Tehran, Iran.



Fateme Tahmasebi is a PhD student in Anatomical Sciences Department at Tehran University, Tehran, Iran. She has obtained her Master's degree in Anatomical Sciences from Tarbiat Modares University, Tehran, Iran. Her Master's thesis was about Poly Cystic Ovary.

Article info:

Received: 05 Apr. 2015

Accepted: 24 Jun. 2015

Key Words:

Duplicated ureter, Accessory renal artery, Congenital anomalies

ABSTRACT

There are often duplicated ureter with types of congenital anomalies and associated clinical complications. The unilateral duplicated ureter was observed as an incidence result in usual dissection. During routine dissection of the body of an adult male with middle-aged 40-50 year old, the duality of unilateral incompletely ureter was seen in above. Two branches of ureter are coalesce in 7 cm distally hilum of kidney and form a unit ureter. Right kidney and ureter were entirely normal. This variation was accruing because ureter bud split incompletely during embryogenesis. Kidney with bifid ureter forms a clear diagnosis of renal failure. These anatomical differences may exhibit pathological obstruction urinary tract and should be considered in endourological method. Awareness of relationship between renal arteries and collecting systems for applications is necessary and vital in endourological procedures and renal surgeries.

1. Introduction

Renal abnormalities form a high percentage of all congenital anomalies that is due to disorder in different stages of development of kidney. Some babies that are born alive, have a developmental abnormality in the urinary tract, often not associated with clinical problems. Renal failure cases in children may be due to developmental defects in ureteral bud, and metanephros. Duplication of ureter is the most common anomaly of urinary

system. This anomaly might be complete or incomplete. Incomplete duplication of ureter is known as bifid ureter. The incomplete duplication is three times more common than complete duplication, with a frequency of one in 500 cases [1]. According to recent studies of Russel et.al was reported average 3% ureteral duplication on routine examination [2].

2. Case Report

In a routine anatomical dissection of an approximately 40-50 years old male Iranian cadaver in the Medical Fac-

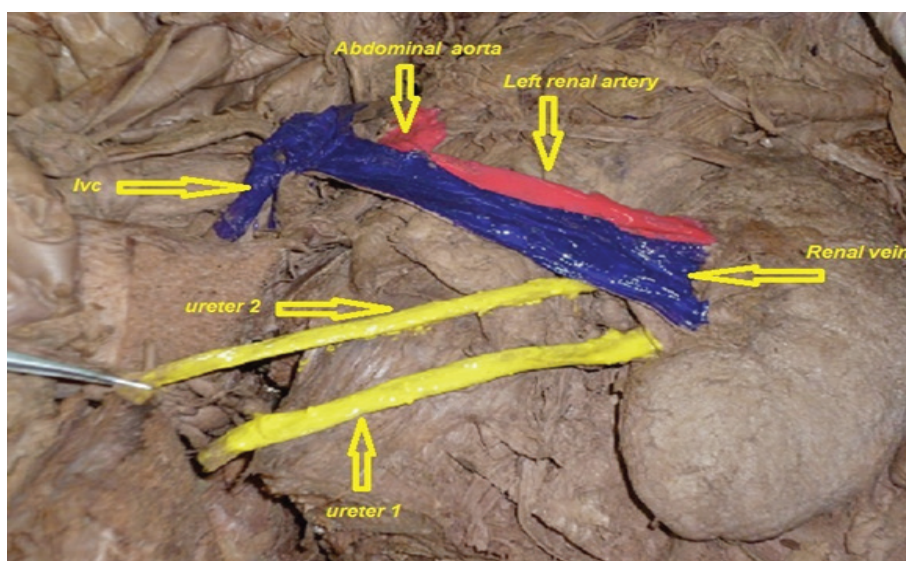
* Corresponding Author:

Zohreh Mazaheri, PhD

Address: Department of Anatomical Sciences, Faculty of Medicine, Tarbiat Modares University, Tehran, Iran.

Tel: +98 (912) 2643483

E-mail: mazaheri2020@yahoo.com



ANATOMICAL SCIENCES

Figure 1. Photograph showing anterior view of left Kidney with bifid ureter, renal artery and renal vein in a male cadaver.

ulty of Tarbiat Modares University, was detected a rare case of a unilateral incompletely duplicated ureter on left kidney. After fixation, was opened abdomen cavity of cadaver, then pushed away abdominal viscera and seen the posterior wall of abdomen, the peritoneal layer was removed, bifid ureter was observed. The ureters were painted in the cadaver that was studied better.

In this case, a bifid ureter was found on the left kidney of cadaver [Figure 1]. Two ureters came out of left kidney, one above the other, these ureters were running parallel to each other and after that they joined together in a single ureter at about a distance of 7 cm distally renal hilum, one ureter enter to bladder. Typically, there is an accessory renal artery, a branch of the abdominal aorta for blood supply of the lower pole of kidney, in similar cases. But in this case there is no accessory renal artery. Pelvis and kidney size were normal in left kidney. Right kidney was normal and had a single ureter. Other abdominal and pelvic viscera structures examined and there was no other associated abnormally in this case.

3. Discussion

The aim of this study was to report a congenital anomaly in urinary system in a cadaveric dissection. Urinary tract during fetal life was produced by pronephros, mesonephros and metanephros. Pronephros has a rudimentary state, without any function and in the fourth week of fetal life disappears. The mesonephroi are functional, having complete, though simple nephrons. The mesonephroi are drained by a pair of mesonephric (wolffian) ducts,

which grow caudally to open into the posterior wall of the primitive urogenital sinus. By the 5th week, a pair of ureteric buds sprouts from the distal mesonephric ducts and induce the overlying sacral intermediate mesoderm to develop into the metanephroi, or definitive kidneys. The definitive kidneys, or metanephroi, are composed of two functional components, the excretory portion and the collecting portion. Formation of the metanephros kidney begins with the induction and formation of a pair of new structures, the ureteric buds, within the intermediate mesoderm of the sacral region. Ureteric buds sprout from the distal portion of the mesonephric ducts on about day 28. The ureteric bud normally does not bifurcate until it enters the substance of the metanephric blastema. Occasionally, however, it bifurcates prematurely, resulting in a Y-shaped bifid ureter [3]. There are reports that showed bifid ureter was observed in other disease such as Goltz syndrome [4], high cephalad kidney, duplication of the pelvis [5], ectopic ureter and contralateral quadrifid ureter, and L3 hemivertebra [6].

This anomaly is associated with other disease conditions but in the present case, the unilateral incomplete bifid ureter in left kidney was no associated with any abnormality.

Thus, most of the reports showed the associated renal or systemic anomalies in cases of duplicated ureters. However Das et al. reported an isolated case of an incompletely duplicated ureter, without any associated congenital anomaly, in an adult female cadaver. Their description is similar to this case [7]. It may further make

urinary tract infection and hydronephrosis [1]. Previous studies showed that there are a lot of diseases related to this anomaly. Nephrolithiasis is most common in persons with an incompletely duplicated ureter [8]. Kao et al. had also reported ureteral cancer in a duplicated ureter [9]. However, individuals with bifid ureters similar this case may remain asymptomatic throughout their lives.

Knowledge of the different anatomical variations of the ureter and kidney can help to recognize different diseases and is of great importance in urinary system surgical procedures.

References

- [1] Fernbach SK, Feinstein KA, Spence K, Lindstorm CA. Ureteral duplication and its complications. *Radiographics*. 1997; 17(1):109-27.
- [2] Williams NS, Bailey H, Bulstrode CJ, Love RM, O'Connell PR. *Bailey & Love's short practice of surgery*. New York: Crc Press; 2008.
- [3] Gunduz K, Gunalp I, Erden I. Focal dermal hypoplasia (Goltz's syndrome). *Ophthalmic Genetics*. 1997; 18(3):143-9.
- [4] Al Attia HM. Cephalad Renal Ectopia duplication of pelvicalyceal system and patent ductus arteriosus in an adult female. *Scandinavian Journal of Urology and Nephrology*. 1999; 33(4):257-9.
- [5] Bhandarkar AD, Raju AM, Rao MS. Single unilateral ectopic bifid ureter with contralateral orthotopicquadrifid ureter, a rare combination. *Journal of Postgraduate medicine*. 1997; 43(4):104-5.
- [6] Das S, Dhar P, Mehra RD. Unilateral Isolated Bifid Ureter. A Case Report. *J Anniston India* 2001;50:43-44.
- [7] Peres LA, Ferreira JR, Beppu AP, de Araújo Junior ER, Vicenzi G, Yamamoto RY. Anatomical alterations in patients with nephrolithiasis. *J Bras Nefrol* 2010;32:33-6.
- [8] Kao JL, Huang CH, Chang YM, Tsai SC, Yang CL, Shiao CC. Ureteral cancer in a duplicated ureter. *Quarterly Journal of Medicine*. 2013 ;106(8):777-8.

